

---

PONTIFÍCIA UNIVERSIDADE CATÓLICA DO RIO GRANDE DO SUL  
PRÓ-REITORIA DE PESQUISA E PÓS-GRADUAÇÃO  
FACULDADE DE MEDICINA  
PROGRAMA DE PÓS-GRADUAÇÃO EM MEDICINA/PEDIATRIA  
E SAÚDE DA CRIANÇA  
MESTRADO EM SAÚDE DA CRIANÇA

**AVALIAÇÃO DA MOBILIDADE DE PREGA VOCAL  
ANTES E DEPOIS DE CIRURGIA CARDIOTORÁCICA  
EM CRIANÇAS**

**LUTHIANA FRICK CARPES**

Dissertação de Mestrado apresentada à  
Faculdade de Medicina da PUCRS para  
obtenção de título de Mestre em Medicina/  
Pediatria

Orientador: Prof. Dr. Carlos Cezar Fritscher  
Co-orientador: Prof. Dr. Humberto Holmer Fiori

Porto Alegre, 2010

---

---

**DADOS INTERNACIONAIS DE CATALOGAÇÃO NA PUBLICAÇÃO (CIP)**

C297a Carpes, Luthiana Frick

Avaliação da mobilidade de prega vocal antes e depois de cirurgia cardiotorácica em crianças / Luthiana Frick Carpes. Porto Alegre: PUCRS, 2010.

74f.: il. tab. Inclui um artigo de periódico submetido à publicação.

Orientador: Prof. Dr. Carlos Cezar Fritscher.

Co-orientador: Prof. Dr. Humberto Holmer Fiori.

Dissertação (Mestrado) – Pontifícia Universidade Católica do Rio Grande do Sul. Faculdade de Medicina. Programa de Pós-Graduação em Medicina. Mestrado em Pediatria e Saúde da Criança.

1. PARALISIA DAS PREGAS VOCAIS. 2. NERVO LARÍNGEO RECORRENTE/lesões. 3. INTUBAÇÃO. 4. PROCEDIMENTOS CIRÚRGICOS TORÁCICOS. 5. PROCEDIMENTOS CIRÚRGICOS CARDÍACOS. 6. CIRURGIA TORÁCICA. 7. COMPLICAÇÕES PÓS-OPERATÓRIAS. 8. CRIANÇA. 9. PRÉ-ESCOLAR. 10. LACTENTE. 11. RECÉM-NASCIDO. 12. ADOLESCENTE. 13. LARINGOSCOPIA. I. Fritscher, Carlos Cezar. II. Fiori, Humberto Holmer. III. Título.

C.D.D. 617.553

C.D.U. 616.225-009.11:616.712-089(043.3)

N.L.M. WV 535

Rosária Maria Lúcia Prenna Geremia  
Bibliotecária CRB 10/196

---

---

MESTRANDA: LUTHIANA FRICK CARPES

ENDEREÇO: RUA CRISTIANO FISCHER, 181 APT 601- PORTO ALEGRE/RS

CEP: 90410-000

E-MAIL: [luthiana@terra.com.br](mailto:luthiana@terra.com.br)

TELEFONE: (51) 97848452

CREMERS: 25178

ÓRGÃO FINANCIADOR: CAPES

CONFLITO DE INTERESSE: NENHUM

---

---

***Dedicatória***

*Dedico aos meus pais.*

*Por estarem sempre presentes apesar da distância.*

*Pelo apoio absoluto à minha busca pelo conhecimento.*

*Por me ensinarem que o estudo é o alicerce de quem somos.*

---

---

## AGRADECIMENTOS

Ao meu pai, pela lição de que o importante é ser e não ter.

À minha mãe, por me ensinar determinação e organização, qualidades imprescindíveis de um pesquisador.

Ao meu irmão Andreio Frick Carpes, por seu amor incondicional.

Ao meu irmão Arturo Frick Carpes, por me mostrar que a residência médica é apenas o começo.

Ao Frederick Kazmir Kozak, por acreditar em meu potencial, por tornar possível a realização da pesquisa, pelo seu incentivo nos momentos em que desanimei, pelo carinho e suporte emocional.

À Marcela Cárdenas Fandino, por me ajudar a crescer como médica e pesquisadora, pelo exemplo de trabalho incansável e de superação dos limites, pela amizade e companheirismo.

Aos cirurgiões cardíacos Jacques Le Blanc e Andrew Campbell, por aceitarem estudo de lesão iatrogênica em seus pacientes cirúrgicos.

Aos anestesistas e enfermeiros (as) do *BC Children's Hospital*, Vancouver, Canadá.

Ao Humberto Holmer Fiori, pela paciência e por me acolher como sua co-orientanda.

À minha grande amiga Amália Moura Jornada, por me estimular a começar o mestrado, pelas longas conversas pela internet e por batalhar por mim, enquanto eu estava em Vancouver.

À secretária Carla Rothmann, por me fazer ser lembrada e pelas sugestões tão valiosas.

A CAPES, pela bolsa do mestrado.

---

---

## SUMÁRIO

### CAPÍTULO I

<b>1 INTRODUÇÃO E JUSTIFICATIVA DO TRABALHO .....</b>	<b>13</b>
<b>1.1 REFERÊNCIAS.....</b>	<b>17</b>

### CAPÍTULO II

<b>2 ARTIGO DE REVISÃO.....</b>	<b>21</b>
<b>RESUMO.....</b>	<b>22</b>
<b>ABSTRACT .....</b>	<b>23</b>
<b>INTRODUCTION .....</b>	<b>24</b>
<b>CONCLUSION .....</b>	<b>42</b>
<b>REFERENCES .....</b>	<b>43</b>

### CAPÍTULO III

<b>3 ARTIGO ORIGINAL.....</b>	<b>49</b>
<b>RESUMO.....</b>	<b>50</b>
<b>ABSTRACT .....</b>	<b>51</b>

---

---

<b>INTRODUCTION .....</b>	<b>52</b>
<b>MÉTODOS.....</b>	<b>54</b>
<b>RESULTS .....</b>	<b>56</b>
<b>DISCUSSION.....</b>	<b>61</b>
<b>CONCLUSION .....</b>	<b>65</b>
<b>REFERENCES .....</b>	<b>66</b>

#### **CAPÍTULO IV**

<b>ANEXO 1- Protocolo do Quality Assurance Project .....</b>	<b>70</b>
--	-----------

---

---

## LISTA DE FIGURAS

### CAPÍTULO II

- Figure I.** Flexible laryngoscopy. A. Complete visualization of vocal folds in abduction. B. Partial visualization of vocal folds in adduction due to supraglottic tissue. Because movements of the supraglottic tissue can occur independently of the vocal ligament and the vocal process it is not possible to assume normal vocal fold movement in this case. .... 28
- Figure II.** Flexible laryngoscopy. A. Right vocal fold in abduction and left vocal fold in paramedian position. B. Right vocal fold in adduction and left vocal fold in paramedian position with an appropriate glottic closure..... 29
- Figure III.** Arnold Chiari Malformation ..... 34
-



---

## LISTA DE TABELAS

### CAPÍTULO II

<b>Table I.</b> Prevalence of VFI on laryngeal examinations.....	24
<b>Table II.</b> Number of cases according to etiology of VFI in previous cohort studies.....	31

### CAPÍTULO III

<b>Table I.</b> Differences on age and weight between children with vocal fold immobility and children with normal movement of the vocal folds following cardiothoracic surgery .....	57
<b>Table II.</b> Differences on possible associated factors between children with VFI and children with normal movement of the vocal folds following cardiothoracic surgery .....	59
<b>Table III.</b> Differences on possible associated factors between children with VFI and children with normal movement of the vocal folds following patent ductus arteriosus ligation.....	60
<b>Table IV.</b> Previous studies of VFI in children following cardiothoracic surgery .....	62

---

---

## LISTA DE ABREVIATURAS

<b>ACM</b>	<i>Arnold Chiari Malformation</i>
<b>ELBW</b>	<i>extremely low birth weight</i>
<b>EMG</b>	<i>electromyography</i>
<b>IPV</b>	imobilidade de prega vocal
<b>NLR</b>	nervo laríngeo recorrente
<b>PDA</b>	<i>patent ductus arteriosus</i>
<b>PDAL</b>	<i>patent ductus arteriosus ligation</i>
<b>RLN</b>	<i>recurrent laryngeal nerve</i>
<b>TEE</b>	<i>transesophageal echocardiography</i>
<b>VFI</b>	<i>vocal fold immobility</i>

---

---

## RESUMO

**Objetivo:** Determinar a incidência de imobilidade de prega vocal (IPV) após cirurgia cardiotorácica e estabelecer os fatores associadas a esse desfecho.

**Métodos:** Laringoscopia flexível para acessar o movimento das pregas vocais foi realizada antes da cirurgia e novamente dentro de 72 horas após a extubação em 100 pacientes pediátricos submetidos a procedimentos cardiotorácicos. Os dois cirurgiões documentaram a técnica cirúrgica e sua impressão de possível lesão do nervo laríngeo recorrente (NLR). Presença de sintomas laríngeos após a extubação foi documentada.

**Resultados:** Das 100 crianças incluídas nesse estudo, 8 apresentavam IPV após a cirurgia. Crianças sem IPV apresentavam idade mais avançada ( $p=0.023$ ) e eram mais pesadas ( $p=0.016$ ). Crianças submetidas a ligadura do ducto arterioso apresentaram risco 9.5 vezes maior de IPV ( $p=0.0009$ ). O uso do cautério se mostrou associado à IPV ( $p=0.039$ ). A chance de IPV foi aumentada em oito vezes ( $p=0.01$ ) e 8.1 vezes ( $p=0.033$ ) em pacientes que apresentavam estridor e rouquidão, respectivamente. Choro fraco também foi significativamente associado à IPV ( $p<0.0001$ ). Sempre que o cirurgião apresentava impressão que o NLR havia sido lesionado a chance de IPV era aumentada em 11.4 vezes ( $p=0.03$ ).

**Conclusões:** Crianças menores e de idade menos avançada que foram submetidas a ligadura do ducto arterioso apresentaram risco maior de IPV após a cirurgia. O uso do cautério foi associado a este desfecho e deve ser evitado sempre que possível. Laringoscopia flexível pós operatória é indicada especialmente se houver impressão do cirurgião de lesão do NLR ou na presença de sintomas laríngeos.

---

---

## ABSTRACT

**Objective:** To determine the incidence of vocal fold immobility (VFI) following cardiothoracic surgery and to establish the associated factors with this outcome.

**Methods:** Flexible laryngoscopy to assess vocal fold mobility was performed prior to surgery and again within 72 hours following extubation in 100 pediatric patients who underwent cardiothoracic procedures. The two operating surgeons recorded the surgical technique and also their impression of possible recurrent laryngeal nerve injury (RLNI). Presence of laryngeal symptoms following extubation was documented.

**Results:** Of the 100 children included in this study, 8 had VFI following surgery. Children without VFI were older ( $p=0.023$ ) and heavier ( $p=0.016$ ). Children who underwent patent ductus arteriosus ligation (PDAL) had increased risk of VFI by 9.5 times ( $p=0.0009$ ). The use of cautery was found to be associated with VFI ( $p=0.039$ ). The chance of VFI was increased by 8 times ( $p=0.01$ ) and 8.1 times ( $p=0.033$ ) in patients displaying stridor and hoarseness, respectively. Weak cry was also significantly associated with VFI ( $p<0.0001$ ). Whenever the surgeon thought there was RLNI, the chance of VFI was increased by 11.4 times ( $p=0.03$ ).

**Conclusions:** Smaller and younger children who underwent PDAL were at higher risk of developing VFI following surgery. The use of cautery was associated with this outcome and should be avoided whenever possible. Postoperative flexible laryngoscopy is indicated especially if there is an impression of RLNI by the surgeon or in the presence of laryngeal symptoms.

---

---

# **CAPÍTULO I**

---

## 1 INTRODUÇÃO E JUSTIFICATIVA

Estudos nas décadas de 60 e 70 documentaram que a imobilidade de prega vocal (IPV) é a segunda causa mais comum de estridor neonatal depois da laringomalácia e que corresponde a 10% de todas as lesões laríngeas congênitas.<sup>1-3</sup> Outros estudos subseqüentes observaram maior prevalência de IPV em crianças com sintomas laríngeos<sup>4,5</sup> e isso provavelmente se deva aos avanços nas técnicas laríngeas diagnósticas e ao aumento na sobrevivência de neonatos prematuros e de crianças submetidas a cirurgias cardiotorácicas. Daya et al.<sup>6</sup> realizaram estudo em 102 crianças com IPV. Dos 102 casos, 44 tiveram como etiologia a iatrogenia, principalmente cirurgia cardíaca. A ligadura do ducto arterioso foi associado a 25 % dos casos iatrogênicos.

A IPV pode afetar as funções laríngeas de respiração, fonação e deglutição. Estridor é o sintoma mais comumente relatado independente da imobilidade ser unilateral ou bilateral.<sup>6-11</sup> Rouquidão, choro fraco e alterações na deglutição incluindo aspiração também compõem o quadro clínico, principalmente em casos unilaterais. Tais alterações na criança em pós-operatório de cirurgia cardíaca têm sérias implicações. Há estudos mostrando que os neonatos submetidos à ligadura do ducto arterioso que apresentem IPV no pós-operatório permanecem por um tempo mais prolongado em ventilação mecânica,<sup>12,13</sup> requerem alimentação via sonda por um período mais longo,<sup>12</sup> e permanecem por mais tempo hospitalizados.<sup>12</sup>

---

Em estudos retrospectivos<sup>14-16</sup> que avaliaram IPV após cirurgia cardíaca pediátrica, apenas pacientes sintomáticos foram incluídos e as crianças assintomáticas não tiveram suas laringes examinadas. Como a IPV pode ser assintomática ou pouco sintomática, os resultados de prevalência destes estudos não são confiáveis. Mais recentemente foram publicados estudos prospectivos em que todas as crianças submetidas ao procedimento cardiorácico foram examinadas, independentemente de serem sintomáticas ou não.<sup>12,13,17,18</sup> Estes estudos mostraram prevalência aumentada de IPV (9% - 52%) quando comparada aos estudos anteriores (2.8% - 8.8%) e confirmaram que IPV em crianças pode ser silenciosa.

É sabido que IPV pode ser familiar,<sup>19</sup> idiopática,<sup>6,11</sup> resultado de trauma de parto,<sup>20</sup> de origem neurológica (especialmente se bilateral),<sup>21</sup> além de complicação da doença cardiológica (síndrome cardiovocal)<sup>22</sup> nos casos de hipertensão da artéria pulmonar e compressão de nervo laríngeo recorrente (NLR) entre esta artéria e o arco aórtico. Sem a visualização do movimento da prega vocal no pré-operatório não se consegue excluir outras possíveis causas de IPV e não se pode afirmar que a IPV tenha sido realmente resultado do procedimento cirúrgico.

IPV pode ser originada em procedimento cirúrgico cardiorácico devido a múltiplos fatores como trauma de intubação com conseqüente fixação laríngea,<sup>23</sup> compressão do ramo anterior do NLR entre o tubo endotraqueal e a cartilagem tireóidea nos casos em que o balonete esteja inflado e posicionado na laringe,<sup>24</sup> compressão do NLR pela sonda da ecocardiografia transesofágica,<sup>25</sup> lesão térmica pelo resfriamento tópico<sup>26</sup> ou pelo uso do cautério, estiramento das artérias subclávias devido à

---

esternotomia mediana<sup>27</sup> ou simplesmente por lesão direta do NLR durante a dissecação cirúrgica.

O presente trabalho apresenta um artigo de revisão sobre IPV em pediatria e um artigo original. O artigo de revisão se intitula “Imobilidade de Prega Vocal em Pediatria: Uma Revisão dos Conceitos Atuais”. É revisão dos artigos pertinentes ao assunto e engloba todos os aspectos desde a terminologia até o tratamento e prognóstico.

O artigo original se intitula “Imobilidade de Prega Vocal após Cirurgia Cardiorácica em Crianças”. Foi resultado de nove meses de estudo e incluiu 100 crianças. O objetivo foi definir a incidência de IPV no pós-operatório de crianças submetidas a procedimentos cirúrgicos cardiorácicos e identificar os fatores associados a ocorrência desse desfecho.

Foi observado um número crescente de crianças com IPV no pós-operatório de cirurgia cardíaca no *BC Children’s Hospital* em 2008. Houve uma preocupação por parte dos cirurgiões cardíacos, cardiologistas, neonatologistas, enfermeiros e otorrinolaringologistas pediátricos em melhor entender esta complicação. Frente a esse assunto tão estimulante e ao apoio de toda a equipe médica, foi desenvolvido protocolo de estudo aprovado como *Quality Assurance Project*.

Foram incluídas no estudo crianças de todas as idades que foram submetidas a procedimentos cardiorácicos no *BC Children’s Hospital*. O *BC Children’s Hospital* é hospital de atendimento quaternário que recebe toda a população da província de British Columbia, no oeste do Canadá. É referência em atendimento cardiológico e realiza uma média de 18 cirurgias cardiorácicas ao mês. Não é realizado neste hospital o

---



procedimento de Norwood, pois se observou que os resultados são inferiores aos dos alcançados pelo grupo de cirurgia cardiotorácica de Edmonton, em Alberta. O procedimento de Norwood abrange a anastomose do tronco principal da artéria pulmonar com a aorta. É necessária dissecação bilateral da caixa torácica a fim de se criar comunicação entre a artéria subclávia direita e a artéria pulmonar para manter o fluxo sanguíneo aos pulmões. Crianças com indicação de tal procedimento são encaminhadas ao *Stollery Hospital*.

O que torna este estudo único é a inclusão de crianças de todas as idades, não só do neonato, além da inclusão de todos os tipos de procedimentos cardiológicos realizados no “BC Children’s Hospital”, e não só a ligadura do ducto arterioso. Outro fator de destaque foi o exame da laringe no pré-operatório e a fim de excluir IPV de outras etiologias. As crianças com tubo endotraqueal no pré-operatório não puderam ter suas laringes examinadas e foram excluídas. Isso determinou a exclusão de muitos neonatos prematuros que foram submetidos à ligadura do ducto arterioso. Houve reflexo disso em nossos resultados, pois este é o grupo de maior risco de IPV no pós-operatório.

Os resultados encontrados não respondem todas as questões, mas desenvolvem hipóteses a serem investigadas e principalmente educam sobre a necessidade de haver uma preocupação com a laringe pediátrica em cirurgias cardiotorácicas.

---

**1.1 REFERÊNCIAS**

1. Dedo DD. Pediatric vocal cord paralysis. *Laryngoscope* 1979;**89**(9 Pt 1):1378-84.
  2. Holinger LD, Holinger PC, Holinger PH. Etiology of bilateral abductor vocal cord paralysis: a review of 389 cases. *Ann Otol Rhinol Laryngol* 1976;**85**(4 Pt 1):428-36.
  3. Holinger PH, Brown WT. Congenital webs, cysts, laryngoceles and other anomalies of the larynx. *Ann Otol Rhinol Laryngol* 1967;**76**(4):744-52.
  4. Berkowitz RG. Neonatal upper airway assessment by awake flexible laryngoscopy. *Ann Otol Rhinol Laryngol* 1998;**107**(1):75-80.
  5. Schild JA, Holinger LD. Peroral endoscopy in neonates. *Int J Pediatr Otorhinolaryngol* 1980;**2**(2):133-8.
  6. Daya H, Hosni A, Bejar-Solar I, Evans JN, Bailey CM. Pediatric vocal fold paralysis: a long-term retrospective study. *Arch Otolaryngol Head Neck Surg* 2000;**126**(1):21-5.
  7. Cohen SR, Geller KA, Birms JW, Thompson JW. Laryngeal paralysis in children: a long-term retrospective study. *Ann Otol Rhinol Laryngol* 1982;**91**(4 Pt 1):417-24.
  8. de Gaudemar I, Roudaire M, Francois M, Narcy P. Outcome of laryngeal paralysis in neonates: a long term retrospective study of 113 cases. *Int J Pediatr Otorhinolaryngol* 1996;**34**(1-2):101-10.
  9. Gentile RD, Miller RH, Woodson GE. Vocal cord paralysis in children 1 year of age and younger. *Ann Otol Rhinol Laryngol* 1986;**95**(6 Pt 1):622-5.
  10. Lee CC, Su BH, Lin HC, Tsai YC, Lin CD, Lin TW. Outcome of vocal cord paralysis in infants. *Acta Paediatr Taiwan* 2004;**45**(5):278-81.
  11. Rosin DF, Handler SD, Potsic WP, Wetmore RF, Tom LW. Vocal cord paralysis in children. *Laryngoscope* 1990;**100**(11):1174-9.
-

12. Clement WA, El-Hakim H, Phillipos EZ, Cote JJ. Unilateral vocal cord paralysis following patent ductus arteriosus ligation in extremely low-birth-weight infants. *Arch Otolaryngol Head Neck Surg* 2008;**134**(1):28-33.
  13. Pereira KD, Webb BD, Blakely ML, Cox CS, Jr., Lally KP. Sequelae of recurrent laryngeal nerve injury after patent ductus arteriosus ligation. *Int J Pediatr Otorhinolaryngol* 2006;**70**(9):1609-12.
  14. Davis JT, Baciewicz FA, Suriyapa S, Vauthy P, Polamreddy R, Barnett B. Vocal cord paralysis in premature infants undergoing ductal closure. *Ann Thorac Surg* 1988;**46**(2):214-5.
  15. Fan LL, Campbell DN, Clarke DR, Washington RL, Fix EJ, White CW. Paralyzed left vocal cord associated with ligation of patent ductus arteriosus. *J Thorac Cardiovasc Surg* 1989;**98**(4):611-3.
  16. Zbar RI, Chen AH, Behrendt DM, Bell EF, Smith RJ. Incidence of vocal fold paralysis in infants undergoing ligation of patent ductus arteriosus. *Ann Thorac Surg* 1996;**61**(3):814-6.
  17. Skinner ML, Halstead LA, Rubinstein CS, Atz AM, Andrews D, Bradley SM. Laryngopharyngeal dysfunction after the Norwood procedure. *J Thorac Cardiovasc Surg* 2005;**130**(5):1293-301.
  18. Smith ME, King JD, Elsherif A, Muntz HR, Park AH, Kouretas PC. Should all newborns who undergo patent ductus arteriosus ligation be examined for vocal fold mobility? *Laryngoscope* 2009;**119**(8):1606-9.
  19. Raza SA, Mahendran S, Rahman N, Williams RG. Familial vocal fold paralysis. *J Laryngol Otol* 2002;**116**(12):1047-9.
  20. Parker LA. Part 1: early recognition and treatment of birth trauma: injuries to the head and face. *Adv Neonatal Care* 2005;**5**(6):288-97; quiz 298-300.
  21. Chen EY, Inglis AF, Jr. Bilateral vocal cord paralysis in children. *Otolaryngol Clin North Am* 2008;**41**(5):889-901, viii.
-

22. Condon LM, Katkov H, Singh A, Helseth HK. Cardiovascular syndrome in infancy. *Pediatrics* 1985;**76**(1):22-5.
  23. Salem MR, Wong AY, Barangan VC, Canalis RF, Shaker MH, Lotter AM. Postoperative vocal cord paralysis in paediatric patients. Reports of cases and a review of possible aetiological factors. *Br J Anaesth* 1971;**43**(7):696-700.
  24. Ellis PD, Pallister WK. Recurrent laryngeal nerve palsy and endotracheal intubation. *J Laryngol Otol* 1975;**89**(8):823-6.
  25. Kawahito S, Kitahata H, Kimura H, Tanaka K, Oshita S. Recurrent laryngeal nerve palsy after cardiovascular surgery: relationship to the placement of a transesophageal echocardiographic probe. *J Cardiothorac Vasc Anesth* 1999;**13**(5):528-31.
  26. Dimarakis I, Protopapas AD. Vocal cord palsy as a complication of adult cardiac surgery: surgical correlations and analysis. *Eur J Cardiothorac Surg* 2004;**26**(4):773-5.
  27. Hamdan AL, Moukarbel RV, Farhat F, Obeid M. Vocal cord paralysis after open-heart surgery. *Eur J Cardiothorac Surg* 2002;**21**(4):671-4.
-

---

## **CAPÍTULO II**

---

## **2 ARTIGO DE REVISÃO**

**IMOBILIDADE DE PREGA VOCAL EM PEDIATRIA:  
UMA REVISÃO DOS CONCEITOS ATUAIS**

**PEDIATRIC VOCAL FOLD IMMOBILITY:  
A REVIEW OF CURRENT CONCEPTS**

---

**RESUMO**

**Introdução:** Imobilidade de prega vocal (IPV) em crianças é uma entidade que desafia o otorrinolaringologista. Os achados clínicos, a etiologia, as ferramentas diagnósticas, e as estratégias de manejo diferem em várias maneiras dos da população adulta.

**Objetivo:** Descrever e discutir os aspectos atuais significativos da IPV em crianças por meio de uma revisão pertinente da literatura.

**Síntese dos achados:** IPV representa 5.2% a 36% dos casos de crianças com sintomas laríngeos. Estridor é o sintoma mais comum independente da imobilidade ser unilateral ou bilateral. A etiologia mais comum de IPV unilateral em crianças é a cirurgia cardiorácica. Os casos bilaterais são mais comumente relacionados a causas neurológicas ou idiopáticas. Laringoscopia flexível é um método diagnóstico seguro que fornece informação confiável. Retorno do movimento ocorre em até 70% dos casos dependendo da etiologia. O manejo depende dos sintomas, do grau de comprometimento da via aérea, da idade, da etiologia e da IPV ser unilateral ou bilateral. Traqueostomia pode ser necessária nos casos bilaterais.

**Conclusão:** IPV é achado frequente em crianças que apresentam sintomas laríngeos especialmente aqueles que foram submetidos à cirurgia cardiorácica. A compensação ou o retorno do movimento são esperados na maioria dos casos e o manejo definitivo só deve ser cogitado após um período de observação maior que 1 ano dependendo da sintomatologia e etiologia.

---

**ABSTRACT**

**Introduction:** Vocal fold immobility (VFI) in children is a challenging disorder for the otolaryngologist. The clinical findings, etiology, diagnostic tools and management strategies differ in many ways from those seen in the adult population.

**Objective:** To describe and discuss the current significant aspects of vocal fold immobility in children through a review of the pertinent literature.

**Data synthesis:** VFI accounts for 5.2% to 36% of the cases of children with laryngeal symptoms. Stridor is the most common symptom regardless if the immobility is unilateral or bilateral. The most common etiology of unilateral VCI in children is cardiothoracic surgery. Bilateral cases are more commonly due to neurological or idiopathic causes. Diagnosis via flexible laryngoscopy is a safe modality and provides reliable information. Recovery of immobility occurs in up to 70% of cases depending on the etiology. Management depends on symptoms, the extent of airway compromise, age, etiology and whether VFI is unilateral or bilateral. Tracheostomy may be necessary in bilateral cases.

**Conclusion:** VFI is a frequent finding in children with laryngeal symptoms particularly those undergoing cardiothoracic surgery. Compensation or recovery is expected in the majority of cases and definitive management should be only advocated after a period of observation usually greater than 1 year and depending on the degree of symptomatology and etiology.

---



## INTRODUCTION

The earliest written reports of childhood vocal fold immobility (VFI) date back to the late 1800s.<sup>1-3</sup> Approximately 10% of congenital laryngeal lesions are due to VFI and it is the second most common cause of neonatal stridor after laryngomalacia.<sup>4-6</sup> Ungkanont et al.<sup>7</sup> reported on 62 neonates who underwent endoscopy in order to diagnose the etiology of stridor, apnea and feeding difficulty. Laryngomalacia was the most common cause of symptoms (19%) followed closely by VFI (13%). However, a higher prevalence of VFI over laryngomalacia was observed in three other cohorts with both congenital and acquired laryngeal lesions that included neonates and older children with laryngeal symptoms<sup>1,8,9</sup> (see table I). Advancement of laryngeal diagnostic techniques along with lower mortality of premature newborns, an increase of children with complex congenital diseases and children undergoing cardiothoracic procedures, may be the cause of the increased incidence of VFI. The otolaryngologist requires a thorough understanding of this entity in order to diagnose and manage this population.

**Table I.** Prevalence of VFI on laryngeal examinations

Author (year)	Subjects	VFI cases		Prevalence
		Unil	Bil	
Cavanagh (1955)	107	27	10	34.5%
Schild (1980)	100	8	28	36%
Ungkanont (1998)	62	4	4	13%
Berkowitz (1998)	110	13	16	26.4%

VFI: vocal fold immobility

Unil: unilateral vocal fold immobility

Bil: bilateral vocal fold immobility

## **ANATOMY AND PHISIOLOGY**

It is important to have a comprehensive understanding of laryngeal anatomy in order to manage a child with VFI. The human larynx is a complex organ that functions as a sphincter at the junction of the digestive and respiratory tracts. It has a significant role related to the physiologic aspects of airway protection, respiration and phonation. Airway protection occurs during the pharyngeal phase of a swallow when the larynx elevates and the vocal folds adduct to prevent a bolus of food from entering the lower respiratory tract. Respiration occurs through the larynx with the vocal folds in an abducted position. The larynx's role in phonation occurs during expiration with the vocal folds in the adducted position. In order to perform these roles, the structures of the larynx interact under precise neural control.<sup>10</sup>

The intrinsic laryngeal muscles are innervated by the superior and inferior laryngeal nerves, collateral branches of the vagus nerve. The superior laryngeal nerve branches into an internal and an external division. The internal division enters the thyrohyoid membrane to provide sensory innervation to the pharyngeal and laryngeal mucosa above the true vocal fold. The external division travels to innervate the cricothyroid muscle. The right inferior laryngeal nerve, or recurrent laryngeal nerve (RLN) branches off the vagus at the level of the subclavian artery and travels posteriorly behind the artery to loop under its proximal portion.<sup>11</sup> Subsequently, the nerve ascends into the neck along the tracheoesophageal groove in a position more lateral than the left recurrent laryngeal nerve.<sup>12</sup> It enters the larynx at the cricothyroid joint and provides

---

motor innervation to all the laryngeal muscles except the cricothyroid muscle as well as sensory innervation to the laryngeal mucosa below the vocal cord. The left vagus nerve takes a similar course in front of the arch of the aorta continuing into the thorax and abdomen. The left RLN arises behind the aorta near the remnant of the ductus arteriosus and ascends to the larynx in the tracheoesophageal groove. Its longer course makes it more susceptible to injury.<sup>11</sup>

The function of the RLN is quite complex. During phonation and coughing the nerve transmits neural impulses from the nucleus ambiguus to induce synchronous and appropriate vocal fold adduction via innervations of the thyroarytenoid, lateral cricoarytenoid, and interarytenoid muscles. Certain portions of the posterior cricoarytenoid muscle may also be stimulated, although more frequently this muscle is inhibited during adduction movement. During inspiration, the RLN produces arytenoid and vocal fold abduction by evoking muscular contraction in the posterior cricoarytenoid muscle, while inhibiting the strongest adductor, the lateral cricoarytenoid muscle.<sup>13</sup>

## **CLINICAL SYMPTOMS**

The most common manifestation of VFI in children, unilateral or bilateral, is stridor.<sup>6,14-19</sup> Infants with unilateral VFI may have a weak, breathy cry and swallowing difficulty such as choking and cyanosis during feeding. Presumably, insensitivity of the hemilarynx contributes to aspiration.<sup>20</sup> Children with bilateral VFI are more prone to develop stridor and dyspnea than dysphonia and aspiration.<sup>11</sup> Some neonates with

---

bilateral VFI require intubation at birth because of severe respiratory distress, whereas others have little or no airway compromise.<sup>21</sup>

Daya et al.<sup>15</sup> observed stridor in 88 (86%) of 102 children with VFI. Of the 49 children with bilateral compromise of the vocal folds, 47 (96%) presented with stridor and only one (2%) and two (4%) presented with dysphonia and difficult feeding respectively. Abnormal cry and hoarseness was present in 27 (51%) of the 53 children with unilateral compromise of the vocal fold and difficulty feeding was observed in 23% of these children.

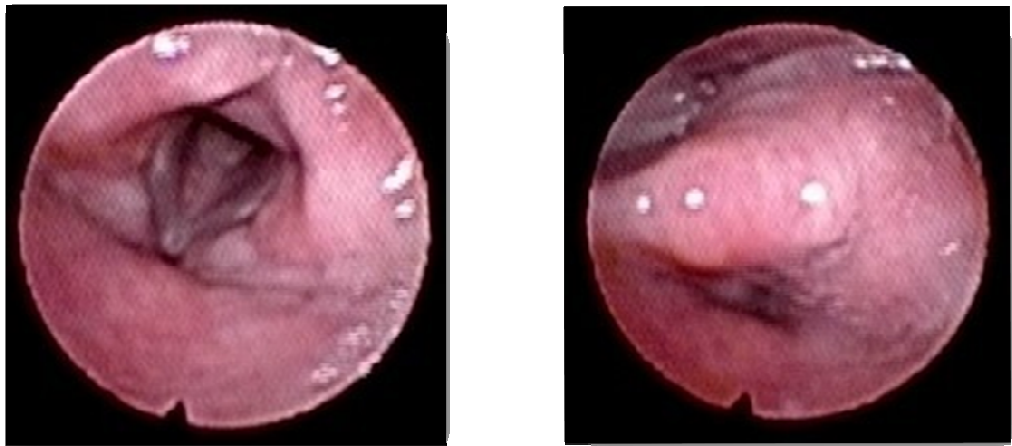
## **DIAGNOSTIC METHODS**

The current diagnostic methods to assess vocal fold movement includes awake flexible endoscopy; rigid endoscopy during recovery from general anaesthesia and laryngeal ultrasound.<sup>22</sup>

The development of flexible fiberoptic instrumentation has allowed awake bedside examination of the pediatric upper airway. It largely overcomes the disadvantages of direct laryngoscopy under general anesthesia, although the information obtained may be somewhat imprecise as the endoscopic view of the vocal folds may be obscured in children due to anatomical differences.<sup>8</sup> Compared to the adult larynx, the pediatric larynx is smaller and the epiglottis may be omega shaped in normal conditions. The arytenoids and the aryepiglottic folds are proportionally larger and the insertion of the vocal folds into the vocal process of the arytenoids is more anterior.<sup>23</sup> Fleischer et

---

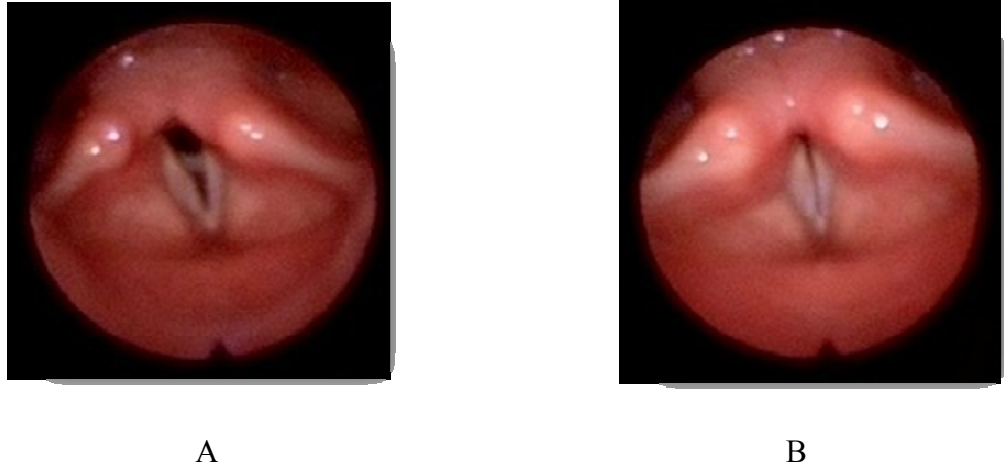
al.<sup>24</sup> observed that movements of the corniculate region can occur independently of the vocal ligament and vocal process, possibly due to variability of innervations patterns of the supraglottis. Whenever the direct visualization of the vocal process is blocked by the supraglottic tissue (see figure I), such as an anterior-medially tilted arytenoid common in VFI cases, the assessment of vocal fold mobility may be erroneous. However, flexible laryngoscopy appears to be a relatively safe procedure that gives reliable clinical information (see figure II).



A

B

**Figure I.** Flexible laryngoscopy. A. Complete visualization of vocal folds in abduction. B. Partial visualization of vocal folds in adduction due to supraglottic tissue. Because movements of the supraglottic tissue can occur independently of the vocal ligament and the vocal process it is not possible to assume normal vocal fold movement in this case.



**Figure II.** Flexible laryngoscopy. A. Right vocal fold in abduction and left vocal fold in paramedian position. B. Right vocal fold in adduction and left vocal fold in paramedian position with an appropriate glottic closure.

Direct laryngoscopy under anesthesia has traditionally been considered as the gold standard for assessment of the airway. It allows palpation of the larynx to investigate mobility of the cricoarytenoid joints and differentiation between laryngeal fixation and true paralysis.<sup>11</sup> This technique has a number of disadvantages, such as, anesthetic risks, need for specific endoscopic equipment and time delay. As well, the evaluation of the movement of the vocal folds is compromised by general anesthesia and the presence of the laryngoscope. The position of the tip of the laryngoscope may immobilize the vocal fold and give the erroneously impression of VFI<sup>25</sup>. A small window of the depth of anesthesia that allows vocal fold mobility with spontaneous ventilation without laryngospasm is essential for the correct diagnosis.<sup>11</sup>

After initially demonstrating that ultrasound can accurately delineate laryngeal anatomy and function in a lamb model, Friedman et al.<sup>25</sup> prospectively performed

laryngeal ultrasounds on 27 children aged 1 day to 14 years. High interrater and intrarater reliability between four ultrasonographers rating 15 normal children and 12 with unilateral VFI was observed. Vats et al.<sup>22</sup> examined the larynx of 55 children with suspected vocal fold immobility. Findings on rigid laryngoscopy under general anesthesia were compared to findings of laryngeal ultrasound and a correlation was observed in 81.8% of cases. Laryngeal ultrasound is less invasive but is operator dependent and is not a standard procedure in many institutions.

## **ETIOLOGY**

The most common etiologies of VFI in children are iatrogenic, neurological diseases, birth trauma and idiopathic (see table II).<sup>14-17,26,27</sup> Cardiothoracic procedures are the most common iatrogenic cause of unilateral VFI in children<sup>15</sup>, and usually affect the left vocal fold.<sup>28</sup> Central neurological disease, such Arnold Chiari malformation (ACM), often affect both vocal folds and should always be investigated in a child with bilateral VFI.<sup>28</sup>

Emery et al.<sup>26</sup> reviewed the etiology of VFI in 71 cases seen over a 20 year period. Nineteen (27%) cases were classified as congenital and 52 (73%) were acquired. Birth trauma and genetics were responsible for 7 and 2 congenital cases, respectively. The remaining 10 congenital cases were idiopathic. In the acquired group, peripheral neurological trauma was the most common etiology and was recognized in 25 (48%) patients. Of these 25 cases, 20 were considered iatrogenic. VFI was secondary to central

---

neurological pathology in 20 cases; 17 of these 20 had bilateral involvement. The remaining 16 children were in the idiopathic group. One child had VFI due to peripheral neuropathy.

**Table II.** Number of cases according to etiology of VFI in previous cohort studies

Author (year)	Total		Iatrogenic		Neurological		Idiopathic		Obstetric		Others	
	Unil	Bil	Unil	Bil	Unil	Bil	Unil	Bil	Unil	Bil	Unil	Bil
<b>Cohen (1982)</b>	36	65	5	4	5	27	17	19	7	12	2	3
<b>Emery (1984)<sup>Ω</sup></b>	40	31	20		4	16	9	7	4	3	1	2
<b>Gentile (1986)</b>	10	12	4	0	1	5	3	3	1	4	0	1
<b>Rosin (1990)<sup>£</sup></b>	22	29	12	4	3	15	8	12	1	1	2	2
<b>de Gaudemar (1996)</b>	61	52	excluded <sup>π</sup>		10	19	23	19	19	5	9	9
<b>Daya (2000)</b>	53	49	39	5	3	13	10	26	0	5	1	0

VFI: vocal fold immobility

Unil: unilateral vocal fold immobility

Bil: bilateral vocal fold immobility

<sup>Ω</sup> It is not reported if unilateral or bilateral in 20 iatrogenic cases; 3 cases of direct accidental external trauma and other 2 cases of cardiomegaly and stretching of the recurrent laryngeal nerve are not represented in the table.

<sup>π</sup> Children with iatrogenic VFI were excluded from the cohort.

<sup>£</sup> Some patients had more than one etiology which was not specified in the original paper.

## 1. Cardiothoracic Procedures

Of 102 children with VFI studied by Daya et al.<sup>15</sup>, iatrogenic causes formed the largest group (43%), with cardiac surgery causing the highest number of cases (33). Another study including 17 cases of VFI in infants 12 months or younger<sup>27</sup> revealed that 8 (47%) had VFI of iatrogenic origin. Of these 8 cases, 2 had repair of complex cardiac anomalies, and six had patent ductus arteriosus ligation (PDAL).



Immobility of the vocal folds is a well known complication in pediatric cardiac surgery. Retrospective studies examined symptomatic children following cardiothoracic procedures and have reported incidences of VFI between 2.8% and 8.8%.<sup>29-32</sup> Since a child with VFI can be asymptomatic or mildly symptomatic<sup>33,34</sup>, the incidence of VFI in these previous studies was probably underestimated. In three prospective studies, flexible laryngoscopy was performed on premature neonates who underwent PDAL in spite of the presence of laryngeal symptoms.<sup>33-35</sup> The prevalence of VFI was 11.5% (7/61) and 16% (14/86) in Pereira et al.<sup>33</sup> and Smith et al.<sup>34</sup> cohorts, respectively. Clement et al.<sup>35</sup> included 18 newborns with extremely low birth weight (ELBW) in their cohort of 23 patients. The incidence of VFI was 52% and when analyzing only the ELBW group the incidence reached 67%. Low birth weight, low weight at surgery, low gestational age and younger age at surgery were significantly associated with VFI.<sup>34,35</sup> Laryngeal symptoms such as stridor and difficulty feeding were not present in every case.<sup>33,34</sup>

Postoperative VFI may be due to direct trauma to the RLN during the surgical procedure and that may explain the relatively high incidence following neck and thoracic operations. However, VFI has been reported in adults following other surgical sites far from the anatomical course of the RLN.<sup>36 37,38</sup> Mechanical laryngeal injury such as dislocation and subluxation of the cricothyroid or cricoarytenoid joints may result from traumatic endotracheal intubation.<sup>39</sup> Another possible mechanism is laryngeal nerve compression via an endotracheal tube with an inflated cuff.<sup>36</sup> Ellis et al. dissected the larynx of adult cadavers in order to investigate this possibility. They observed that it is not possible to exert any pressure on the nerve when it is in the tracheoesophageal

---

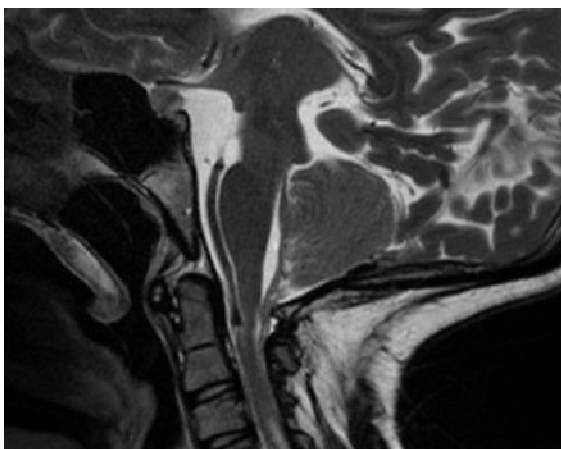
groove or on its posterior branch. However, the anterior branch passes medial to the lamina of the thyroid cartilage to supply the lateral cricoarytenoid and thyroarytenoid muscles and can be compressed between the cuff and the thyroid lamina when the cuff is inflated within the larynx.<sup>36</sup> Endotracheal intubation with a cuffed tube in children still remains to be investigated as a possible etiology of VFI.

## **2. Neurological Causes**

Neurological causes have been implicated in 16% to 32% of cases of VFI in children. In bilateral cases of VFI, 27.5% to 52% have a central neurological pathology as etiology.<sup>14,15,17,26</sup> A central neurologic process leading to intracranial hypertension may result in vocal fold dysfunction probably due to stretching, compression, or ischemia of the vagus nerve during its intracranial course.<sup>40</sup> The tenth cranial nerve exits the brain stem within the spinal canal and courses superiorly through the foramen magnum to exit the jugular foramen which leaves it vulnerable to injury.<sup>4</sup>

The most common neurological disorder implicated in VFI is ACM (see figure III).<sup>2</sup> In 16 patients with VFI due to a neurological disorder studied by Daya et al.<sup>15</sup>, ACM was the most common condition and occurred in 7 patients (44%). All 7 had bilateral VFI. Disorders such as brain stem or cerebral dysgenesis, hydrocephalus, encephalocele, leukodystrophy, spina bifida, cerebral palsy, myasthenia gravis, fascioscapulohumeral myopathy, and spinal muscular atrophy have also been associated with VFI<sup>21</sup>.

---



**Figure III.** Arnold Chiari Malformation

### 3. Idiopathic

Idiopathic VFI is considered whenever a detailed history and full workup cannot identify any other etiology. In many studies, idiopathic VFI is one of the most common causes of pediatric laryngeal immobility, accounting for 22.5% to 41% of the cases in a variety of series.<sup>14,15,17,26,27</sup> It may be equivalent to a viral neuropathy similar to Bell palsy or sudden sensorineural hearing loss.<sup>2,41</sup> Chitose et al.<sup>42</sup> observed significant changes in serum levels of varicella zoster virus antibody in five adults with idiopathic VFI. Rizzardia et al.<sup>43</sup> recently reported a case of VFI in a newborn with congenital varicella syndrome. This newborn presented with respiratory distress in the first hour of life and unilateral VFI was observed the following day. Serologic tests confirmed varicella zoster virus infection both in the mother and the child. It cannot be discounted that the VFI in this case report was of an idiopathic congenital cause. The frequency of virus infection as the etiology of childhood VFI remains unknown.

---

#### **4. Birth Trauma**

Birth trauma is defined as an injury sustained during the process of labour and delivery<sup>44</sup>. Advancements in obstetrical management over the past several decades, such as elective cesarean deliveries for suspected macrosomia and/or breech presentation, have significantly decreased the incidence of birth trauma.<sup>45</sup> During delivery, vocal fold injury may occur when the laryngeal nerves are overstretched.<sup>46</sup> In breech babies, traction applied to the shoulders to accelerate delivery may stretch the RLNs. Similar stretching could occur in a vertex presentation if traction is applied to the head and neck to help deliver disproportionately broad shoulders.<sup>1</sup> Of 102 children with VFI studied by Daya et al.<sup>15</sup>, five had symptoms presenting at birth and a documented history of birth trauma. All of these patients had bilateral dysfunction of the vocal folds and 80% resulted from forceps delivery.

#### **MANAGEMENT**

In adults it is generally accepted to wait a period of 6 to 12 months for spontaneous recovery of vocal fold movement before considering any procedure to alleviate symptoms.<sup>47</sup> Palliative cases may supercede this statement. In children, spontaneous recovery of the vocal fold has been known to occur in 48% to 64% of the cases<sup>14-17,26</sup>, and there are reports of recovery after 9<sup>26</sup> and 11 years.<sup>15</sup>

Daya et al.<sup>15</sup> reported recovery in 36 (56%) of 64 children with follow-up records; of these 36 patients, 25 (69%) recovered within 2 years. Differences between

---

the etiological groups were observed. Children with VFI secondary to neurological causes had the highest recovery rate (71%); all of these patients recovered within 2 years and all had bilateral VFI. In the idiopathic group, 64% recovered within a range of 6 months to 11 years. In five patients with bilateral VFI (18%) recovery occurred between 5 to 11 years. Of the patients with VFI secondary to surgery, 46% recovered within 5 years.

Management of VFI depends primarily on the patient's symptoms, particularly the extent of airway compromise, age, etiology of VFI and whether there is unilateral or bilateral compromise of the vocal folds. Treatment of the underlying neurological or cardiological disease may allow full recovery of laryngeal function. Emery et al.<sup>26</sup> observed vocal fold movement recovery in 5 (62%) of 8 children with meningomielocele and ACM who received shunt decompression for associated hydrocephalus. Condon et al.<sup>48</sup> observed normal vocal fold movement after repair of cardiac disease in two infants with cardiovascular syndrome (hypertension of the pulmonary artery causing compression of the RLN against the aortic arch).

### **1. Tracheotomy**

The immobility of the vocal folds, especially if bilateral, can lead to significant airway compromise and the need for a tracheotomy. In 1986, Tucker<sup>49</sup> stated that virtually all children with bilateral VFI require tracheotomy. Further studies have shown a tendency for more conservative management. Rosin et al.<sup>19</sup> observed that 19 (66%) of 29 children who had bilateral VFI required tracheotomy. In a cohort of 102 children with

---

VFI, 35 underwent tracheotomy; 28 (57%) of the 49 children with bilateral VFI and 7 (13%) of 53 children with unilateral VFI<sup>15</sup>. Previous reports of neonatal unilateral VFI have shown that tracheotomy is not necessary.<sup>17,26,27</sup> In those cases of unilateral VFI requiring tracheotomy there are often associated conditions such as chronic lung disease, subglottic stenosis or tracheomalacia.<sup>14,15</sup> Children with VFI who have stable respiratory status, normal growth and development, reliable caretakers and living in close proximity to urgent medical care, do not require tracheotomy. However, these children need frequent, regular follow-up appointments with routine flexible laryngoscopic examinations. Children who do not qualify to the criteria above deserve consideration of the benefit securing the airway via a tracheotomy.<sup>11</sup>

## **2. Surgical management of bilateral VFI**

Surgical management on bilateral VFI is generally undertaken in order to decannulate patients with a tracheotomy. It is advocated to wait 12 months or even longer before any surgical intervention in anticipation of decannulation because of the relatively high rate of spontaneous resolution of VFI.<sup>11</sup> There are several different surgical techniques; each with different rates of decannulation and potential complications such as vocal folds damage and aspiration. The challenging is to maintain the balance between a patent airway, preserving the voice and swallowing function and avoiding aspiration. As none of these procedures reconstructs the dynamic sphincter function of the larynx, none is perfect.<sup>11</sup> Gupta et al.<sup>50</sup> found no significant difference in the decannulation rates of laser cordectomy (80%), arytenoidectomy with vocal fold

---

lateralization (70%), and endoscopic vocal fold lateralization (66.7%). In 2002, a retrospective systematic review was conducted in order to determine the impact of various surgical procedures for bilateral VFI in children. Decannulation rate for external arytenoidopexy via lateral cervical or laryngofissure was 19 of 24 (79%), external arytenoidectomy was 14 of 19 (74%), CO<sup>2</sup> laser arytenoidectomy was 4 of 10 (40%), and costal cartilage graft procedure was 2 of 2 (100%). Cordotomy and laryngeal reinnervation were not included in this review. External arytenoid procedures were statistically significant more efficacious than CO<sup>2</sup> laser procedures in terms of primary decannulation ( $p=0.02$ ). Endoscopic arytenoidectomy and posterior cricoid cartilage grafting were considered to be better reserved for revision procedures.<sup>51</sup>

Posterior cricoid grafting is a relatively new technique used for the treatment of bilateral VFI. In 1994, Gray et al.<sup>52</sup> described three pediatric cases of neurogenic bilateral VFI treated with this technique via laryngofissure. All three children were decannulated with no aspiration. Inglis et al.<sup>53</sup> reported their experience on endoscopic posterior cricoid split and rib graft insertion for airway expansion in bilateral VFI and subglottis stenosis. Decannulation was achieved in 5 out of 7 cases with no morbidity, in particular no aspiration. Patients with associated severe subglottic stenosis were considered poor candidates.

### **3. Surgical management on unilateral VFI**

Management of the neonate with unilateral VFI should be conservative, except when significant airway distress is present. In the neonate with airway distress secondary

---

to unilateral VFI, tracheotomy may be necessary, although this is extremely rare.<sup>3</sup> Unilateral VFI can affect the laryngeal mechanism of airway protection and/or phonation. Several conservative therapeutic techniques can be employed to improve phonation or decrease aspiration including speech therapy, nursing in the upright position, thickening feeds and anti-reflux therapy.<sup>10</sup> According to Benjamin<sup>28</sup>, aspiration associated to unilateral VFI in an infant is usually a self limited problem and conservative treatment should be advocated. However, in rare situations where aspiration symptoms are more severe, tracheostomy, nasogastric feeding or gastrostomy tube placement is recommended while waiting for spontaneous recovery.

Older children with unilateral VFI presenting with dysphonia may benefit from speech therapy. It may be prudent to wait until puberty for spontaneous recovery of vocal fold movement since poor voice quality is not a life-threatening condition. However, a chronic voice disorder can affect self-image, self-confidence, career opportunities and recreational pursuits.<sup>54</sup> With greater degree of surgical medialization of the immobile vocal fold an improved quality of voice can be achieved. In children with persistent dysphonia who do not respond to speech therapy, injection laryngoplasty, thyroplasty, arytenoid adduction and laryngeal reinnervation may be considered. The ideal procedure should provide the maximum amount of medialization of the immobile vocal fold, minimize the postoperative impairment of the airway and allow for additional augmentation later in life as the child and larynx grow.<sup>55</sup>

There are a variety of choices for materials in injection laryngoplasty, including fat, collagen, hyaluronic acid gel, and calcium hydroxylapatite.<sup>56</sup> Because of the well-known potential for granuloma formation, Teflon has fallen out of favour in the

---



treatment of VFI.<sup>3</sup> Daya et al.<sup>15</sup> reported that three children in their cohort had medialization procedures. Two of these children had unilateral left VFI following cardiac surgery and underwent Teflon injection at 18 months and 5 years after surgery. One patient developed a granuloma that required surgical removal and the other achieved a successful outcome with an improvement in voice. Fat injection, another option frequently employed in the adult population, requires a significant overinjection due to expected reabsorption. This makes airway obstruction much more likely to occur in the immediate postoperative period.<sup>55</sup>

In 1974, Isshiki et al.<sup>57</sup> described the type I thyroplasty, a reversible procedure which involved medializing the vocal fold via a window created in the thyroid cartilage and holding the fold in the desired position with an autologous cartilage graft implant. The operation was originally described under local anesthesia with sedation to allow the voice to be monitored during the procedure. Because many children are not able to undergo phonosurgery under local anesthesia, Gardner et al.<sup>55</sup>, performed type I thyroplasty with silastic implant for vocal fold medialization in two children aged 4 and 8 years under general anesthesia. Flexible laryngoscopy performed through the laryngeal mask allowed the surgeon to see the endolarynx during the procedure and good outcome was achieved. The authors advocated that medialization laryngoplasty with a silastic implant allows for precise medialization with no need for overcorrection and granulomas have not been reported with silastic. The procedure is reversible and as the child grows a larger implant can be utilized as needed.

In 2007, Sipp et al.<sup>58</sup> reported 15 children with unilateral VFI who underwent 27 procedures for medialization of the vocal fold. The procedures included 19 injection

---

---

laryngoplasties, 3 thyroplasties, 2 ansa cervicalis - RLN reinnervation procedures, 1 adduction arytenoidopexy, and 1 cricothyroid joint subluxation. All children had good voice outcome. One child acquired aspiration pneumonia after thyroplasty under local anesthesia. The authors stated that thyroplasty could be considered for prepubescent children with aspiration in addition to voice concerns or older adolescents with good airway protection who can tolerate a procedure under local anesthesia. They also stated that laryngeal mask airway with flexible laryngoscopy is the appropriate anesthesia method for an uncooperative patient or a patient with impaired airway protection, but they believe that this method is inferior for obtaining good voice outcome.

Following research in a canine model where the sternohyoid–ansa cervicalis nerve-muscle pedicle was successfully applied to the posterior cricoarytenoid muscle, Tucker<sup>49</sup> reviewed his experience with pediatric unilateral VFI. He reported that three of eight small infants with unilateral VFI and tracheotomy underwent surgical nerve-muscle pedicle application to laryngeal adductors. All three infants were successfully decannulated with good voice outcomes within 3 months after surgery. Smith et al.<sup>54</sup> assessed the outcomes of management of unilateral VFI by ansa cervicalis-RLN reinnervation in 6 adolescents. Favourable voice outcomes were observed and the authors stated that this procedure is an appropriate option for dysphonia and glottal incompetence in this age group. Of the two children who underwent ansa cervicalis-RLN anastomosis in the series of Sipp et al.<sup>58</sup>, one had what was considered excellent outcome (immobilized vocal fold assumed a more median position, strong mucosal wave, and less vocal fold atrophy on stroboscopic examination) and the other was able to attain full vocal fold closure 1 year following the procedure. The authors stated that a

---

reinnervation procedure does not alter the laryngeal skeleton and would not complicate additional phonosurgery if needed later in life. The procedure, however, negates any chance of spontaneous recovery of vocal fold movement.

## **CONCLUSION**

VFI is a frequent finding during the laryngeal examination of children with stridor, dysphonia and feeding difficulty. Children with a history of birth trauma, neurological disease or undergoing cardiothoracic surgery are at greater risk. Awake flexible laryngoscopy in the clinic or at the bedside appears to be a safe procedure that provides reliable information and should be considered as the preferential method of diagnosis. Children with bilateral VFI may not need a tracheostomy as long as there is stable respiratory status, normal growth and development, reliable caretakers and living in close proximity to urgent medical care. Recovery is expected in the majority of cases and definitive management should be only advocated after a period of observation of 1 year or greater and depending on the symptomatology. Several types of surgical procedures for unilateral and bilateral VFI have been described. Careful judgement is necessary since there is no perfect procedure and spontaneous recovery of vocal fold function may occur even after several years.

---

## REFERENCES

1. Cavanagh F. Vocal palsies in children. *J Laryngol Otol* 1955;**69**(6):399-418.
  2. de Jong AL, Koppersmith RB, Sulek M, Friedman EM. Vocal cord paralysis in infants and children. *Otolaryngol Clin North Am* 2000;**33**(1):131-49.
  3. Parikh SR. Pediatric unilateral vocal fold immobility. *Otolaryngol Clin North Am* 2004;**37**(1):203-15.
  4. Dedo DD. Pediatric vocal cord paralysis. *Laryngoscope* 1979;**89**(9 Pt 1):1378-84.
  5. Holinger PH, Brown WT. Congenital webs, cysts, laryngoceles and other anomalies of the larynx. *Ann Otol Rhinol Laryngol* 1967;**76**(4):744-52.
  6. Holinger LD, Holinger PC, Holinger PH. Etiology of bilateral abductor vocal cord paralysis: a review of 389 cases. *Ann Otol Rhinol Laryngol* 1976;**85**(4 Pt 1):428-36.
  7. Ungkanont K, Friedman EM, Sulek M. A retrospective analysis of airway endoscopy in patients less than 1-month old. *Laryngoscope* 1998;**108**(11 Pt 1):1724-8.
  8. Berkowitz RG. Neonatal upper airway assessment by awake flexible laryngoscopy. *Ann Otol Rhinol Laryngol* 1998;**107**(1):75-80.
  9. Schild JA, Holinger LD. Peroral endoscopy in neonates. *Int J Pediatr Otorhinolaryngol* 1980;**2**(2):133-8.
  10. Patel NJ, Kerschner JE, Merati AL. The use of injectable collagen in the management of pediatric vocal unilateral fold paralysis. *Int J Pediatr Otorhinolaryngol* 2003;**67**(12):1355-60.
  11. Chen EY, Inglis AF, Jr. Bilateral vocal cord paralysis in children. *Otolaryngol Clin North Am* 2008;**41**(5):889-901, viii.
  12. Arantes A, Gusmao S, Rubinstein F, Oliveira R. [Microsurgical anatomy of the recurrent laryngeal nerve: applications on the anterior approach to the cervical spine]. *Arq Neuropsiquiatr* 2004;**62**(3A):707-10.
  13. Crumley RL. Laryngeal synkinesis revisited. *Ann Otol Rhinol Laryngol* 2000;**109**(4):365-71.
-

14. Cohen SR, Geller KA, Birns JW, Thompson JW. Laryngeal paralysis in children: a long-term retrospective study. *Ann Otol Rhinol Laryngol* 1982;**91**(4 Pt 1):417-24.
  15. Daya H, Hosni A, Bejar-Solar I, Evans JN, Bailey CM. Pediatric vocal fold paralysis: a long-term retrospective study. *Arch Otolaryngol Head Neck Surg* 2000;**126**(1):21-5.
  16. de Gaudemar I, Roudaire M, Francois M, Narcy P. Outcome of laryngeal paralysis in neonates: a long term retrospective study of 113 cases. *Int J Pediatr Otorhinolaryngol* 1996;**34**(1-2):101-10.
  17. Gentile RD, Miller RH, Woodson GE. Vocal cord paralysis in children 1 year of age and younger. *Ann Otol Rhinol Laryngol* 1986;**95**(6 Pt 1):622-5.
  18. Lee CC, Su BH, Lin HC, Tsai YC, Lin CD, Lin TW. Outcome of vocal cord paralysis in infants. *Acta Paediatr Taiwan* 2004;**45**(5):278-81.
  19. Rosin DF, Handler SD, Potsic WP, Wetmore RF, Tom LW. Vocal cord paralysis in children. *Laryngoscope* 1990;**100**(11):1174-9.
  20. Benjamin B. Vocal cord paralysis, synkinesis and vocal fold motion impairment. *ANZ J Surg* 2003;**73**(10):784-6.
  21. Ahmad SM, Soliman AM. Congenital anomalies of the larynx. *Otolaryngol Clin North Am* 2007;**40**(1):177-91, viii.
  22. Vats A, Worley GA, de Bruyn R, Porter H, Albert DM, Bailey CM. Laryngeal ultrasound to assess vocal fold paralysis in children. *J Laryngol Otol* 2004;**118**(6):429-31.
  23. Sapienza CM, Ruddy BH, Baker S. Laryngeal structure and function in the pediatric larynx: clinical applications. *Lang Speech Hear Serv Sch* 2004;**35**(4):299-307.
  24. Fleischer S, Schade G, Hess MM. Office-based laryngoscopic observations of recurrent laryngeal nerve paresis and paralysis. *Ann Otol Rhinol Laryngol* 2005;**114**(6):488-93.
  25. Friedman EM. Role of ultrasound in the assessment of vocal cord function in infants and children. *Ann Otol Rhinol Laryngol* 1997;**106**(3):199-209.
  26. Emery PJ, Fearon B. Vocal cord palsy in pediatric practice: a review of 71 cases. *Int J Pediatr Otorhinolaryngol* 1984;**8**(2):147-54.
-

27. Zbar RI, Smith RJ. Vocal fold paralysis in infants twelve months of age and younger. *Otolaryngol Head Neck Surg* 1996;**114**(1):18-21.
  28. Benjamin BN, Gray SD, Bailey CM. Neonatal vocal cord paralysis. *Head Neck* 1993;**15**(2):169-72.
  29. Davis JT, Baciewicz FA, Suriyapa S, Vauthy P, Polamreddy R, Barnett B. Vocal cord paralysis in premature infants undergoing ductal closure. *Ann Thorac Surg* 1988;**46**(2):214-5.
  30. Fan LL, Campbell DN, Clarke DR, Washington RL, Fix EJ, White CW. Paralyzed left vocal cord associated with ligation of patent ductus arteriosus. *J Thorac Cardiovasc Surg* 1989;**98**(4):611-3.
  31. Liang CD, Ko SF, Huang SC, Huang CF, Niu CK. Vocal cord paralysis after transcatheter coil embolization of patent ductus arteriosus. *Am Heart J* 2003;**146**(2):367-71.
  32. Zbar RI, Chen AH, Behrendt DM, Bell EF, Smith RJ. Incidence of vocal fold paralysis in infants undergoing ligation of patent ductus arteriosus. *Ann Thorac Surg* 1996;**61**(3):814-6.
  33. Pereira KD, Webb BD, Blakely ML, Cox CS, Jr., Lally KP. Sequelae of recurrent laryngeal nerve injury after patent ductus arteriosus ligation. *Int J Pediatr Otorhinolaryngol* 2006;**70**(9):1609-12.
  34. Smith ME, King JD, Elsherif A, Muntz HR, Park AH, Kouretas PC. Should all newborns who undergo patent ductus arteriosus ligation be examined for vocal fold mobility? *Laryngoscope* 2009;**119**(8):1606-9.
  35. Clement WA, El-Hakim H, Phillipos EZ, Cote JJ. Unilateral vocal cord paralysis following patent ductus arteriosus ligation in extremely low-birth-weight infants. *Arch Otolaryngol Head Neck Surg* 2008;**134**(1):28-33.
  36. Ellis PD, Pallister WK. Recurrent laryngeal nerve palsy and endotracheal intubation. *J Laryngol Otol* 1975;**89**(8):823-6.
  37. Minuck M. Unilateral vocal-cord paralysis following endotracheal intubation. *Anesthesiology* 1976;**45**(4):448-9.
-

38. Kikura M, Suzuki K, Itagaki T, Takada T, Sato S. Age and comorbidity as risk factors for vocal cord paralysis associated with tracheal intubation. *Br J Anaesth* 2007;**98**(4):524-30.
  39. Salem MR, Wong AY, Barangan VC, Canalis RF, Shaker MH, Lotter AM. Postoperative vocal cord paralysis in paediatric patients. Reports of cases and a review of possible aetiological factors. *Br J Anaesth* 1971;**43**(7):696-700.
  40. Chaten FC, Lucking SE, Young ES, Mickell JJ. Stridor: intracranial pathology causing postextubation vocal cord paralysis. *Pediatrics* 1991;**87**(1):39-43.
  41. Kothur K, Singh M, Dayal D, Gupta AK. Bilateral idiopathic vocal cord palsy. *Pediatr Emerg Care* 2007;**23**(3):171-2.
  42. Chitose SI, Umeno H, Hamakawa S, Nakashima T, Shoji H. Unilateral associated laryngeal paralysis due to varicella-zoster virus: virus antibody testing and videofluoroscopic findings. *J Laryngol Otol* 2008;**122**(2):170-6.
  43. Rizzardi E, Tagliaferro T, Snijders D, et al. Unilateral laryngeal paralysis in a newborn with congenital varicella syndrome. *Int J Pediatr Otorhinolaryngol* 2009;**73**(1):115-8.
  44. Becerra JE, Fry YW, Rowley DL. Morbidity estimates of conditions originating in the perinatal period: United States, 1986 through 1987. *Pediatrics* 1991;**88**(3):553-9.
  45. Puza S, Roth N, Macones GA, Mennuti MT, Morgan MA. Does cesarean section decrease the incidence of major birth trauma? *J Perinatol* 1998;**18**(1):9-12.
  46. Parker LA. Part 1: early recognition and treatment of birth trauma: injuries to the head and face. *Adv Neonatal Care* 2005;**5**(6):288-97; quiz 298-300.
  47. Tucker HM. Human laryngeal reinnervation. *Laryngoscope* 1976;**86**(6):769-79.
  48. Condon LM, Katkov H, Singh A, Helseth HK. Cardiovascular syndrome in infancy. *Pediatrics* 1985;**76**(1):22-5.
  49. Tucker HM. Vocal cord paralysis in small children: principles in management. *Ann Otol Rhinol Laryngol* 1986;**95**(6 Pt 1):618-21.
  50. Gupta AK, Mann SB, Nagarkar N. Surgical management of bilateral immobile vocal folds and long-term follow-up. *J Laryngol Otol* 1997;**111**(5):474-7.
-

51. Brigger MT, Hartnick CJ. Surgery for pediatric vocal cord paralysis: a meta-analysis. *Otolaryngol Head Neck Surg* 2002;**126**(4):349-55.
  52. Gray SD, Kelly SM, Dove H. Arytenoid separation for impaired pediatric vocal fold mobility. *Ann Otol Rhinol Laryngol* 1994;**103**(7):510-5.
  53. Inglis AF, Jr., Perkins JA, Manning SC, Mouzakes J. Endoscopic posterior cricoid split and rib grafting in 10 children. *Laryngoscope* 2003;**113**(11):2004-9.
  54. Smith ME, Roy N, Stoddard K. Ansa-RLN reinnervation for unilateral vocal fold paralysis in adolescents and young adults. *Int J Pediatr Otorhinolaryngol* 2008;**72**(9):1311-6.
  55. Gardner GM, Altman JS, Balakrishnan G. Pediatric vocal fold medialization with silastic implant: intraoperative airway management. *Int J Pediatr Otorhinolaryngol* 2000;**52**(1):37-44.
  56. Hughes RG, Morrison M. Vocal cord medialization by transcutaneous injection of calcium hydroxylapatite. *J Voice* 2005;**19**(4):674-8.
  57. Isshiki N, Morita H, Okamura H, Hiramoto M. Thyroplasty as a new phonosurgical technique. *Acta Otolaryngol* 1974;**78**(5-6):451-7.
  58. Sipp JA, Kerschner JE, Braune N, Hartnick CJ. Vocal fold medialization in children: injection laryngoplasty, thyroplasty, or nerve reinnervation? *Arch Otolaryngol Head Neck Surg* 2007;**133**(8):767-71.
-



---

## **CAPÍTULO III**

---

**3 ARTIGO ORIGINAL**

**AVALIAÇÃO DA MOBILIDADE DE PREGA VOCAL  
ANTES E DEPOIS DE CIRURGIA CARDIOTORÁCICA  
EM CRIANÇAS**

**ASSESSMENT OF VOCAL FOLD MOBILITY  
BEFORE AND AFTER CARDIOTHORACIC SURGERY  
IN CHILDREN**

---

**RESUMO**

**Objetivo:** Determinar a incidência de imobilidade de prega vocal (IPV) após cirurgia cardiotorácica e estabelecer os fatores associadas a esse desfecho.

**Métodos:** Laringoscopia flexível para acessar o movimento das pregas vocais foi realizada antes da cirurgia e novamente dentro de 72 horas após a extubação em 100 pacientes pediátricos submetidos a procedimentos cardiotorácicos. Os dois cirurgiões documentaram a técnica cirúrgica e sua impressão de possível lesão do nervo laríngeo recorrente (NLR). Presença de sintomas laríngeos após a extubação foi documentada.

**Resultados:** Das 100 crianças incluídas nesse estudo, 8 apresentavam IPV após a cirurgia. Crianças sem IPV apresentavam idade mais avançada ( $p=0.023$ ) e eram mais pesadas ( $p=0.016$ ). Crianças submetidas a ligadura do ducto arterioso apresentaram risco 9.5 vezes maior de IPV ( $p=0.0009$ ). O uso do cautério se mostrou associado à IPV ( $p=0.039$ ). A chance de IPV foi aumentada em oito vezes ( $p=0.01$ ) e 8.1 vezes ( $p=0.033$ ) em pacientes que apresentavam estridor e rouquidão, respectivamente. Choro fraco também foi significativamente associado à IPV ( $p<0.0001$ ). Sempre que o cirurgião apresentava impressão que o NLR havia sido lesionado a chance de IPV era aumentada em 11.4 vezes ( $p=0.03$ ).

**Conclusões:** Crianças menores e de idade menos avançada que foram submetidas a ligadura do ducto arterioso apresentaram risco maior de IPV após a cirurgia. O uso do cautério foi associado a este desfecho e deve ser evitado sempre que possível. Laringoscopia flexível pós operatória é indicada especialmente se houver impressão do cirurgião de lesão do NLR ou na presença de sintomas laríngeos.

---

**ABSTRACT**

**Objective:** To determine the incidence of vocal fold immobility (VFI) following cardiothoracic surgery and to establish the associated factors with this outcome.

**Methods:** Flexible laryngoscopy to assess vocal fold mobility was performed prior to surgery and again within 72 hours following extubation in 100 pediatric patients who underwent cardiothoracic procedures. The two operating surgeons recorded the surgical technique and also their impression of possible recurrent laryngeal nerve injury (RLNI). Presence of laryngeal symptoms following extubation was documented.

**Results:** Of the 100 children included in this study, 8 had VFI following surgery. Children without VFI were older ( $p=0.023$ ) and heavier ( $p=0.016$ ). Children who underwent patent ductus arteriosus ligation (PDAL) had increased risk of VFI by 9.5 times ( $p=0.0009$ ). The use of cautery was found to be associated with VFI ( $p=0.039$ ). The chance of VFI was increased by 8 times ( $p=0.01$ ) and 8.1 times ( $p=0.033$ ) in patients displaying stridor and hoarseness, respectively. Weak cry was also significantly associated with VFI ( $p<0.0001$ ). Whenever the surgeon thought there was RLNI, the chance of VFI was increased by 11.4 times ( $p=0.03$ ).

**Conclusions:** Smaller and younger children who underwent PDAL were at higher risk of developing VFI following surgery. The use of cautery was associated with this outcome and should be avoided whenever possible. Postoperative flexible laryngoscopy is indicated especially if there is an impression of RLNI by the surgeon or in the presence of laryngeal symptoms.

---

## INTRODUCTION

The most common etiologies of pediatric vocal fold immobility (VFI) are iatrogenic, neurological diseases, birth trauma and idiopathic.<sup>1-6</sup> In 2000, a retrospective chart review of 102 consecutive pediatric cases of VFI, Daya et al.<sup>2</sup> reported that the most common etiology was iatrogenic (43%), in particularly cardiothoracic surgery (33 out of 44 iatrogenic cases).

The recurrent laryngeal nerve (RLN) branches off the vagus nerve at the level of the subclavian artery on the right side and at the level of the aortic arch on the left side. The right RLN travels medially and then inferiorly in relation to the subclavian artery, loops under its proximal part and ascends medially towards the larynx. The left RLN descends medially and passes left of the remnant of the ductus arteriosus and then ascends medially toward the tracheoesophageal groove.<sup>7</sup> Compression of the RLN or its anterior branch by a cuffed endotracheal tube<sup>8</sup>; mechanical laryngeal trauma resulting in dislocation and subluxation of the cricothyroid or cricoarytenoid joints<sup>9</sup>; median sternotomy and excessive sternal traction resulting in the application of longitudinal strain to both RLNs via forces generated from the lateral traction of both subclavian arteries<sup>10</sup>; compression of the RLN on the tracheoesophageal groove by a transesophageal echocardiographic probe<sup>11</sup>, thermal trauma from topical cardioprotective cooling<sup>12</sup> or electrocautery; and direct surgical injury by stretching or cutting the RLN are all possible mechanisms of VFI following a cardiothoracic procedure.

---

Previous retrospective studies observed a prevalence of VFI following cardiothoracic surgery in children between 2.8% and 8.8%<sup>13-16</sup>. In these cohorts only symptomatic children had their larynx examined. Since a child with VFI can be asymptomatic or mildly symptomatic<sup>17,18</sup>, the incidence of VFI in these previous studies was probably underestimated. More recently, four other prospective studies observed prevalence of VFI in children who underwent cardiothoracic procedures between 9% and 52%<sup>17-20</sup>. The higher prevalence in prospective studies is partially explained by the fact that every child had their larynx examined following the cardiothoracic procedure, regardless if laryngeal symptoms were present or not.

To date there is no known study with vocal fold assessment before and after the cardiothoracic procedure, therefore other possible etiologies of VFI such as birth trauma<sup>21</sup>, familial<sup>22</sup>, previous cardiothoracic procedure or even cardiovascular syndrome<sup>23</sup> (a hypertense pulmonary artery that compresses the left recurrent laryngeal nerve between the aorta and the trachea) cannot be ruled out.

The aim of this study was to determine the incidence of VFI following cardiothoracic surgery and to attempt to establish the associated factors with this outcome.

---

## **METHODS**

All pediatric patients who underwent cardiothoracic surgery at BC Children's Hospital between November 19, 2008 and August 19, 2009 were included in this study. Patients were excluded whenever flexible laryngoscopy was not undertaken before the surgical procedure due to endotracheal intubation. Patients with VFI prior to surgery were also excluded. Informed consent for flexible laryngoscopy was undertaken and this study initially received institutional approval as a quality assurance review and subsequently full ethics approval from the institutional review board.

Flexible laryngoscopy was performed immediately prior to surgery in the operating room and again within 72 hours following extubation. A flexible laryngoscope, Vision Sciences ENT 1000 which has an external diameter of 2.4 mm was utilized. The scope was attached to a microcamera and a recording system that permitted storage of the video stream images.

The following information was obtained from the patient's chart:

1. Baseline demographics such as date of birth, age at surgery, weight at surgery and cardiothoracic diagnosis.

2. Possible associated factors such as length of intubation, intraoperative transesophageal echocardiography (TEE) monitoring, site of thoracotomy, circulatory arrest, topical cooling, bypass, use of cautery and structures dissected [patent ductus arteriosus (PDA), aortic arch, descending aorta, ascending aorta, main pulmonary artery, left pulmonary artery and right pulmonary artery].

3. Length of hospital stay and intensive care unit stay.

---

Following surgery, the operating surgeons recorded if the RLN was visualized during surgery and their impression of possible RLN injury (RLNI). Laryngeal symptoms including stridor, hoarseness and type of cry were documented following extubation.

Descriptive statistical analysis was performed to characterize and study the groups. Wilcoxon non-parametric tests were used for variables with asymmetrical distribution. Fisher exact tests were used with a significance level of  $p=0.05$ . Relative risks and 95% confidence intervals were calculated. Multivariate analysis was performed with the factors that were significantly associated to VFI on univariate analysis.

---



## RESULTS

Between August 19, 2008 and November 19, 2009, 161 children underwent cardiothoracic surgery at BC Children's Hospital. Of these 161 children, 24 (15%) could not have their larynx examined before surgery because of endotracheal intubation and 4 (2.5%) presented with VFI before surgery and therefore were excluded. Of the remaining 133 children, 25 (18.8%) had no consent by the legal guardian, and 8 (6%) were not examined before surgery because of a lack of communicating that a cardiothoracic surgical procedure was to take place to the investigating team. The remaining 100 children were included in the study.

Of these 100 children, 41 were female and 59 were male. Median age was 19.2 months (IQR 9.9 - 87.7) and median weight was 7.5 Kg (IQR 4.8 - 14.9) at the time of the surgery.

The prevalence of VFI following cardiothoracic surgery was 8% (2.5% - 13.4%). All eight VFI cases were unilateral and left sided. Children without VFI were older ( $p=0.023$ ) and heavier ( $p=0.016$ ) at the time of the surgery (see table I). One surgeon performed 59% of the surgeries and the other 41%. No difference on VFI frequency was observed between the two surgeons ( $p=0.3$ ). Cautery was used for dissection and homeostasis in all patients with VFI (see table II). Circulatory arrest, dissection of the PDA, descending aorta, right and left pulmonary arteries were statistically significantly associated with VFI (see table II). The chance of VFI presenting postoperatively was found to be increased in children whose surgeon had the impression that there was injury of the RLN during surgery and in children displaying stridor, weak cry and hoarseness

---

(see table II). Interestingly, there was a higher chance of VFI whenever the RLN was visualized by the cardiac surgeon (see table II). There was no difference on length of endotracheal intubation ( $p=0.1$ ), length of hospital stay ( $p=0.27$ ) or length of intensive care unit stay ( $p=0.23$ ) between the VFI and non VFI cases. Multivariate analysis did not show any association between possible associated factors and VFI.

**Table I.** Differences on age and weight between children with vocal fold immobility and children with normal movement of the vocal folds following cardiothoracic surgery.

Groups	VFI	Non VFI	<i>P</i> value <sup>‡</sup>
Age (months)	1.87 (0.33 – 32.3)	20.1 (10.7 – 93.7)	0.023
Weight (Kilograms)	3.7 (3.1 – 8.8)	7.8 (4.9 – 15.3)	0.016

Median (interquartile range)

VFI: vocal fold immobile

<sup>‡</sup> Wilcoxon non-parametric test

The groups that were excluded because of previous VFI or because of endotracheal intubation prior to the cardiothoracic procedure were younger ( $p=0.000$ ), had lower weight at surgery ( $p=0.000$ )\_and had more children who underwent PDA ligation (PDAL) ( $p<0.0018$ )\_when compared to the study group. No differences were observed on use of cautery ( $p=0.48$ ), circulatory arrest ( $p=0.42$ ), dissections of the left pulmonary artery ( $p=0.5$ ), right pulmonary artery ( $p=0.23$ ) or descending aorta ( $p=0.15$ ).

No differences on age at surgery ( $p=0.1$ ), weight at surgery ( $p=0.16$ ), use of cautery ( $p=0.13$ ), circulatory arrest ( $p=0.37$ ), PDAL ( $p=0.33$ ) or dissections of the left pulmonary artery ( $p=0.46$ ), right pulmonary artery ( $p=0.32$ ) or descending aorta ( $p=0.38$ ) were observed between the study group and the children whose legal guardians

did not consent and children who were not scoped prior to the cardiothoracic procedure due to lack of communication between the cardiothoracic and investigating teams.

One of the 8 children with VFI died during admission due to complications of cardiac surgery. Recovery of vocal fold movement was observed in 3 out of 7 children on assessment at 3 months follow up. No differences on possible associated factors were observed between children who recovered and the ones who did not recover.

### **Subgroup analysis: PDAL cases**

Seven out of eight children with VFI underwent PDAL (3 of 18 children who underwent PDAL alone and 4 of 24 children who underwent PDAL in combination with a more complex surgical procedure). Of the 42 cases of PDAL, the incidence of VFI was 16.7% (5.1% - 28.2%). All ligations were performed with a suture. There was no statistical significant difference on weight at surgery ( $p=0.09$ ) and age at surgery ( $p=0.12$ ) between the VFI and non VFI cases. Of the possible associated factors, the presence of laryngeal symptoms (stridor, hoarseness and weak cry) following extubation, circulatory arrest, visualization of the RLN by the surgeon and surgeon's impression of RLN injury reached significance (see table III). There was no difference on length of endotracheal intubation ( $p=0.08$ ), length of hospital stay ( $p=0.42$ ) or length of intensive care unit stay ( $p=0.19$ ) between VFI and non VFI cases in this subgroup of patients.

---

**Table II.** Differences on possible associated factors between children with VFI and children with normal movement of the vocal folds following cardiothoracic surgery.

Possible associated factors	VFI 8 children	Non VFI 92 children	RR (95% CI)	P value
Surgeons' impression on RLN injury	3	2	11.4 (3.7 - 34.7)	0.003
Stridor	2	4	8 (2.4 - 26.7)	0.01
Weak cry	8	7	Cell contain zero <sup>Ω</sup>	< 0.0001
Hoarseness	5	12	8.1 (2.1 - 31)	0.033
Cautery	8	60	Cell contain zero <sup>Ω</sup>	0.039
Transesophageal echocardiogram	2	56	0.24 (0.05 - 1.14)	0.056
Circulatory arrest	3	5	6.9 (2 - 23.7)	0.016
Topical cooling	3	32	1.1 (0.3 - 4.4)	0.58
Bypass	5	70	0.4 (0.1 - 1.5)	0.18
Median sternotomy	5	78	4 (1 - 16.3)	0.074
Nerve visualization	6	15	11.3 (2.5 - 52)	0.0009
Aortic Arch	3	16	2.6 (0.7 - 9.8)	0.17
Patent ductus arteriosus	7	35	9.7 (1.2 - 75.6)	0.009
Ascending aorta	5	78	0.3 (0.09 - 1.3)	0.13
Main pulmonary artery	4	41	1.2 (0.3 - 4.6)	0.52
Descending aorta	4	11	5.7 (1.6 - 20)	0.016
Right pulmonary artery	5	23	4.2 (1.1 - 16.7)	0.037
Left pulmonary artery	5	19	5.2 (1.3 - 20)	0.018

VFI: vocal fold immobility

RLN: recurrent laryngeal nerve

<sup>μ</sup> Fisher exact test

<sup>Ω</sup> If one of the cells contain zero (every child with VFI had a weak cry and had the cautery used for dissection and homeostasis), it is not possible to calculate relative risk

RR: relative risk

CI: confidence interval

**Table III.** Differences on possible associated factors between children with VFI and children with normal movement of the vocal folds following patent ductus arteriosus ligation.

Possible associated factors	VFI 7 children	Non VFI 35 children	RR (95% CI)	P value
Surgeons' impression on RLN injury	3	0	Cell contain zero <sup>Ω</sup>	0.003
Stridor	3	3	4.5 (1.3 - 15.3)	0.047
Weak cry	7	3	Cell contain zero <sup>Ω</sup>	< 0.0001
Hoarseness	5	4	9.1 (2.2 - 40)	0.025
Cautery	7	24	Cell contain zero <sup>Ω</sup>	0.097
Transesophageal echocardiogram	2	21	0.3 (0.07 - 1.5)	0.13
Circulatory arrest	3	1	7.1 (2.4 - 21.1)	0.01
Topical cooling	3	14	1.1 (0.3 - 4.3)	0.6
Bypass	4	14	0.7 (0.2 - 2.9)	0.49
Median sternotomy	4	26	2.4 (0.6 - 10.3)	0.22
Nerve visualization	6	10	9.7 (1.3 - 73.7)	0.008
Aortic Arch	3	11	1.5 (0.4 - 5.8)	0.43
Ascending aorta	4	25	0.6 (0.1 - 2.3)	0.37
Main pulmonary artery	4	16	1.5 (0.4 - 5.7)	0.44
Descending aorta	4	8	3.3 (0.9 - 12.7)	0.09
Right pulmonary artery	4	8	3.3 (0.9 - 12.7)	0.09
Left pulmonary artery	4	9	2.9 (0.8 - 11.4)	0.12

VFI: vocal fold immobility

RLN: recurrent laryngeal nerve

<sup>Ω</sup> Fisher exact test

<sup>Ω</sup> If one of the cells contain zero (every child with VFI had a weak cry and had the cautery used for dissection and homeostasis), it is not possible to calculate relative risk

RR: relative risk

CI: confidence interval

## DISCUSSION

The incidence of VFI in pediatric patients who underwent cardiothoracic surgery at our institution was 8% (2.5% - 13.4%). Previous studies where every child, despite the presence of symptoms, had their larynx examined following a cardiothoracic procedure had a prevalence varying from 9% to 52% of VFI (see table IV).<sup>17-20</sup> There are three possible explanations for our relatively lower frequency. First, we included children who underwent all types of cardiothoracic surgeries and not only PDAL. In our cohort, we observed that PDAL increased the risk of VFI by 9.7 times (1.2 - 75.6) and analysis of children who underwent PDAL revealed a much higher incidence of VFI [16.7% (5.1%, 28.2%)]. In fact seven out of eight cases of VFI had PDAL and the remaining child underwent ligation of a previous left Blalock-Taussig shunt that required similar dissection. The second reason for our lower frequency is that we did excluded children who had VFI prior to the cardiothoracic procedure. Flexible laryngoscopy performed prior to surgery in our population revealed four cases of VFI. Interestingly, these four children had a history of previous cardiothoracic surgery. As well, because children with endotracheal intubation prior to the cardiothoracic procedure could not undergo examination of the larynx before hand, most of the premature newborns who were surgical candidates were excluded from our cohort. We did observe that this excluded group was younger and smaller at surgery and also had more PDAL.

Younger age at surgery and lower weight at surgery was significantly associated with VFI. Previous studies have also showed that children with VFI were smaller at birth<sup>16,19</sup>, more premature<sup>16,18,19</sup>, smaller at PDAL<sup>16,18</sup> and younger at PDAL<sup>16,18</sup> when compared to children without VFI.

---

**Table IV.** Previous studies of VFI in children following cardiothoracic surgery

Author (year)	Number of subjects/cases	Type of surgery	Prevalence
Davis (1988)	106/3	PDAL	2.8%
Fan (1989)	167/7	PDAL	4.2%
Zbar (1996)	68/6	PDAL	8.8%
Liang (2003)	75/3	PDA coil embolization	4%
Skinner (2005)	33/3	Norwood procedure	9%
	16/4	Aortic arch reconstruction	25%
Pereira (2006)	61/7	PDAL	11.5%
Clement (2008)	23/12	PDAL	52%
Smith (2009)	86/14	PDAL	16%
Current study	100/8	Cardiothoracic procedures	8% <sup>‡</sup>

VFI: vocal fold immobility

PDAL: patent ductus arteriosus ligation

‡: in this case it is incidence

The length of endotracheal intubation was not different between VFI and non VFI cases and there were no reports of traumatic endotracheal intubation. We did not perform electromyography or palpation of the cricoarytenoid joint to rule out laryngeal fixation because these are invasive procedures that require general anesthesia. Our results suggest that VFI was probably a result of RLN injury during surgery and not from the endotracheal tube.

The use of cautery for dissection and homeostasis of the surgical procedure was performed in all VFI cases and was significantly associated with VFI. No other previous study has showed this association. Demyelination within the RLN following thermal injury was the proposed mechanism. However, topical cooling, another possible source of thermal injury of the RLN within the tracheoesophageal groove was not associated with VFI. Research in cats has showed that coagulation is capable of causing demyelination within the optic nerve when used on the nerve sheath, particularly monopolar electrocautery.<sup>24</sup> Bipolar electrocautery is the preferred method by the cardiac

surgeons at our institution and was used exclusively.

Circulatory arrest was significantly associated to VFI. It was performed whenever it was necessary to dissect out or operate on a blood-filled structure that could not be isolated from the rest of the circulation, mostly aortic arch repair with dissection all the way down to the PDA and therefore very close to the RLN. This is also the case in left pulmonary plasty surgery with dissection through the pericardium and therefore close to the RLN. Circulatory arrest is performed under hypothermia, usually at 18 degrees and most patients also received topical cooling. We found a statistically significant association between circulatory arrest and topical cooling and dissection of the left pulmonary artery. Bypass on the other hand was not associated with VFI.

TEE nearly reached statistical significance but surprisingly children who had intraoperative TEE monitoring had less chance of developing VFI. Kawahito et al.<sup>11</sup> also found no association between TEE and VFI in 116 patients over 5 years of age who underwent cardiothoracic surgery.

Stridor, hoarseness and weak cry were strongly associated with VFI. Possible bias is the fact that assessment of the symptoms was performed frequently at the same time of flexible laryngoscopic examination with visualization of the vocal fold status. This bias could have been avoided if voices of all children had been recorded and further analyzed by another pediatric otolaryngologist blinded for the laryngeal images. This study is underway.

Impression of RLN injury by the surgeon was highly associated to VFI. An interesting finding is that whenever the surgeon visualized the nerve there was a higher

---



---

risk of VFI. Normally the pediatric cardiothoracic surgeons do not search for the RLN and when this nerve is visualized it is because they are obviously in close proximity of the nerve in the field of dissection. In thyroid surgeries it is a standard of care to identify the RLN in order to avoid potential VFI<sup>25</sup>. In this situation when the nerve is visualized there is usually enough room to avoid significant cautery or traction injury. However, in pediatric cardiothoracic surgery the surgeon has already dissected or cauterized too close to the RLN when the nerve is seen. A possible way to identify the RLN intraoperatively without dissecting too closely is via electromyography. Odegard et al.<sup>26</sup> developed a technique to monitor RLN during video-assisted thoracoscopic surgery for PDAL. A probe allowed direct stimulation of the left RLN inside the thorax and needle electrodes placed percutaneously in the neck allowed recording of evoked electromyograms from both RLNs by a neurologic monitor. Left RLN electromyographies were easily obtained in 59 of the 60 children studied and the authors concluded that this technique was easy to perform and was effective in identifying position of the RLN.

Other dissected structures besides PDAL were found to be statistically significantly associated to VFI (right and left pulmonary arteries and descending aorta). In addition to the close proximity of these structures and the RLN, the dissection of the right and left pulmonary arteries were associated to the use of cautery and the descending aorta is frequently dissected on PDAL. Multivariate analysis failed to demonstrate these confounding factors possibly due to the small number of cases with VFI.

---

**CONCLUSION**

The incidence of VFI in children who underwent cardiothoracic surgery is higher in PDAL and in smaller and younger children. The use of cautery is an associated factor that was present in all cases of VFI and probably should be avoided whenever possible. Although circulatory arrest, dissections of the descending aorta, right and left pulmonary arteries were found to be associated to VFI they are probably confounding factors. Further study with a greater number of patients and multivariate analysis is required to definitively establish the associations. Postoperative flexible laryngoscopy is indicated especially if there is an impression of RLNI or the presence of laryngeal symptoms. Consideration of preoperative flexible laryngoscopy in this patient population should also be undertaken.

---

## REFERENCES

1. Cohen SR, Geller KA, Birns JW, Thompson JW. Laryngeal paralysis in children: a long-term retrospective study. *Ann Otol Rhinol Laryngol* 1982;91(4 Pt 1):417-24.
  2. Daya H, Hosni A, Bejar-Solar I, Evans JN, Bailey CM. Pediatric vocal fold paralysis: a long-term retrospective study. *Arch Otolaryngol Head Neck Surg* 2000;126(1):21-5.
  3. de Gaudemar I, Roudaire M, Francois M, Narcy P. Outcome of laryngeal paralysis in neonates: a long term retrospective study of 113 cases. *Int J Pediatr Otorhinolaryngol* 1996;34(1-2):101-10.
  4. Emery PJ, Fearon B. Vocal cord palsy in pediatric practice: a review of 71 cases. *Int J Pediatr Otorhinolaryngol* 1984;8(2):147-54.
  5. Lee CC, Su BH, Lin HC, Tsai YC, Lin CD, Lin TW. Outcome of vocal cord paralysis in infants. *Acta Paediatr Taiwan* 2004;45(5):278-81.
  6. Zbar RI, Smith RJ. Vocal fold paralysis in infants twelve months of age and younger. *Otolaryngol Head Neck Surg* 1996;114(1):18-21.
  7. Monfared A, Kim D, Jaikumar S, Gorti G, Kam A. Microsurgical anatomy of the superior and recurrent laryngeal nerves. *Neurosurgery* 2001;49(4):925-32; discussion 932-3.
  8. Ellis PD, Pallister WK. Recurrent laryngeal nerve palsy and endotracheal intubation. *J Laryngol Otol* 1975;89(8):823-6.
  9. Salem MR, Wong AY, Barangan VC, Canalis RF, Shaker MH, Lotter AM. Postoperative vocal cord paralysis in paediatric patients. Reports of cases and a review of possible aetiological factors. *Br J Anaesth* 1971;43(7):696-700.
  10. Hamdan AL, Moukarbel RV, Farhat F, Obeid M. Vocal cord paralysis after open-heart surgery. *Eur J Cardiothorac Surg* 2002;21(4):671-4.
  11. Kawahito S, Kitahata H, Kimura H, Tanaka K, Oshita S. Recurrent laryngeal nerve palsy after cardiovascular surgery: relationship to the placement of a transesophageal echocardiographic probe. *J Cardiothorac Vasc Anesth* 1999;13(5):528-31.
-

12. Dimarakis I, Protopapas AD. Vocal cord palsy as a complication of adult cardiac surgery: surgical correlations and analysis. *Eur J Cardiothorac Surg* 2004;26(4):773-5.
  13. Davis JT, Baciewicz FA, Suriyapa S, Vauthy P, Polamreddy R, Barnett B. Vocal cord paralysis in premature infants undergoing ductal closure. *Ann Thorac Surg* 1988;46(2):214-5.
  14. Fan LL, Campbell DN, Clarke DR, Washington RL, Fix EJ, White CW. Paralyzed left vocal cord associated with ligation of patent ductus arteriosus. *J Thorac Cardiovasc Surg* 1989;98(4):611-3.
  15. Liang CD, Ko SF, Huang SC, Huang CF, Niu CK. Vocal cord paralysis after transcatheter coil embolization of patent ductus arteriosus. *Am Heart J* 2003;146(2):367-71.
  16. Zbar RI, Chen AH, Behrendt DM, Bell EF, Smith RJ. Incidence of vocal fold paralysis in infants undergoing ligation of patent ductus arteriosus. *Ann Thorac Surg* 1996;61(3):814-6.
  17. Pereira KD, Webb BD, Blakely ML, Cox CS, Jr., Lally KP. Sequelae of recurrent laryngeal nerve injury after patent ductus arteriosus ligation. *Int J Pediatr Otorhinolaryngol* 2006;70(9):1609-12.
  18. Smith ME, King JD, Elsherif A, Muntz HR, Park AH, Kouretas PC. Should all newborns who undergo patent ductus arteriosus ligation be examined for vocal fold mobility? *Laryngoscope* 2009;119(8):1606-9.
  19. Clement WA, El-Hakim H, Phillipos EZ, Cote JJ. Unilateral vocal cord paralysis following patent ductus arteriosus ligation in extremely low-birth-weight infants. *Arch Otolaryngol Head Neck Surg* 2008;134(1):28-33.
  20. Skinner ML, Halstead LA, Rubinstein CS, Atz AM, Andrews D, Bradley SM. Laryngopharyngeal dysfunction after the Norwood procedure. *J Thorac Cardiovasc Surg* 2005;130(5):1293-301.
  21. Parker LA. Part 1: early recognition and treatment of birth trauma: injuries to the head and face. *Adv Neonatal Care* 2005;5(6):288-97; quiz 298-300.
  22. Raza SA, Mahendran S, Rahman N, Williams RG. Familial vocal fold paralysis. *J Laryngol Otol* 2002;116(12):1047-9.
-

- 
23. Condon LM, Katkov H, Singh A, Helseth HK. Cardiovascular syndrome in infancy. *Pediatrics* 1985;76(1):22-5.
  24. Schietroma JJ, Tenzel RR. The effects of cautery on the optic nerve. *Ophthalmol Plast Reconstr Surg* 1990;6(2):102-7.
  25. Steurer M, Passler C, Denk DM, Schneider B, Niederle B, Bigenzahn W. Advantages of recurrent laryngeal nerve identification in thyroidectomy and parathyroidectomy and the importance of preoperative and postoperative laryngoscopic examination in more than 1000 nerves at risk. *Laryngoscope* 2002;112(1):124-33.
  26. Odegard KC, Kirse DJ, del Nido PJ, et al. Intraoperative recurrent laryngeal nerve monitoring during video-assisted thoracoscopic surgery for patent ductus arteriosus. *J Cardiothorac Vasc Anesth* 2000;14(5):562-4.
-

---

## **CAPÍTULO IV**

---

## ANEXO

**Protocolo do *Quality Assurance Project*****\*Dates: DD/MM/YYYY****Demographics:**

Unique ID: \_\_\_\_\_ Name: \_\_\_\_\_

DOB: \_\_\_/\_\_\_/\_\_\_\_\_\* Birth weight (grams): \_\_\_\_\_

Gestational age (weeks): \_\_\_\_\_ Gender: M F

Date of admission: \_\_\_/\_\_\_/\_\_\_\_\_\* Date of hospital discharge: \_\_\_/\_\_\_/\_\_\_\_\_\*

**Pre Surgery Assessment:**Data collector: LC \_\_\_\_InitialsHistory of ETT: No YesDate of intubation: \_\_\_/\_\_\_/\_\_\_\_\_\* Cuffed Uncuffed Size: \_\_\_\_\_

Date of extubation: \_\_\_/\_\_\_/\_\_\_\_\_\*

NG tube: No Yes

Date of insertion: \_\_\_/\_\_\_/\_\_\_\_\_\*

Date of removal (if applicable): \_\_\_/\_\_\_/\_\_\_\_\_\*

Cardiac diagnosis: \_\_\_\_\_  
\_\_\_\_\_Syndrome: No Yes

If yes, specify: \_\_\_\_\_

Neurological abnormality: No Yes

If yes, specify: \_\_\_\_\_

Presence of symptoms:

Stridor: No Yes Unable to identifyHoarseness: No Yes Unable to identifyWeak cry: No Yes Unable to identify

**Flexible Laryngoscopy Pre Surgery:**

Examiner:  LC     \_\_\_\_\_ Initials

Exam date: \_\_\_ / \_\_\_ / \_\_\_\_\_ \*

Right vocal fold:  moving     moving partially     immobile     unable to identify

Left vocal fold:  moving     moving partially     immobile     unable to identify

Exam complications:  No     Yes, which? \_\_\_\_\_

\_\_\_\_\_

Comment on findings: \_\_\_\_\_

\_\_\_\_\_



**Surgery Information:**Data collector:  LC  \_\_\_\_\_ Initials

Surgery date: \_\_\_\_/\_\_\_\_/\_\_\_\_\_\*

Age at surgery (weeks): \_\_\_\_\_ Weight at surgery (grams): \_\_\_\_\_

Surgeon: \_\_\_\_\_

Surgical procedure: \_\_\_\_\_

Surgical technique:

 Right thoracotomy  Left thoracotomy  Median sternotomyStructures dissected:  RPA  LPA  Aortic arch  Descending aorta  PDAIf yes for PDA:  ligated  dividedIf PDA ligation:  suture  clipSurgical dissection via cautery:  No  YesTransesophageal echocardiography:  No  YesCirculatory arrest:  No  YesTopical cooling:  No  YesETT:  Cuffed  Uncuffed Size: \_\_\_\_\_

Bypass time (minutes): \_\_\_\_\_

Central line:  Right  Left  Jugular  SubclavianSurgeon impression on recurrent nerve: Visualized:  No  YesInjured:  No  YesIf yes:  Stretched Cut partially Cut completely

**Post Surgery Assessment:**

Data collector:  LC  \_\_\_\_\_ Initials

Date of NICU discharge: \_\_\_\_/\_\_\_\_/\_\_\_\_\_\*

**ETT:**  No  Yes

If yes: Date of intubation: \_\_\_\_/\_\_\_\_/\_\_\_\_\_\*  Cuffed  Uncuffed Size:

Date of extubation: \_\_\_\_/\_\_\_\_/\_\_\_\_\_\*

Extubation failures:  No  Yes

If yes, how many? \_\_\_\_\_

**NG tube:**  No  Yes

If yes: Date of insertion: \_\_\_\_/\_\_\_\_/\_\_\_\_\_\*

Date of removal (if applicable): \_\_\_\_/\_\_\_\_/\_\_\_\_\_\*

NG tube at hospital discharge:  No  Yes

Gastrostomy tube insertion:  No  Yes

Presence of symptoms:

Stridor:  No  Yes  Unable to identify

Hoarseness:  No  Yes  Unable to identify

Weak cry:  No  Yes  Unable to identify

**Flexible Laryngoscopy Post Surgery:**

**(prior to NICU discharge)**

Examiner:  LC  \_\_\_\_\_ Initials

Exam date: \_\_\_\_/\_\_\_\_/\_\_\_\_\_\*

Right vocal fold:  moving  moving partially  immobile  unable to identify

Left vocal fold:  moving  moving partially  immobile  unable to identify

Exam complications:  No  Yes, which? \_\_\_\_\_

\_\_\_\_\_

Comment on findings: \_\_\_\_\_

\_\_\_\_\_

**Follow-up:**

4th month   8th month   12th month

Examiner: LC   \_\_\_\_\_Initials

Date of assessment: \_\_\_\_/\_\_\_\_/\_\_\_\_\*

Recovery: No   Yes

If no: contra lateral compensation: No   Yes

Laryngeal surgery indicated: No   Yes, which?

Presence of symptoms:

Stridor: No   Yes   Unable to identify

Hoarseness: No   Yes   Unable to identify

Weak cry: No   Yes   Unable to identify

---