

Length of the drilling holes of zygomatic implants inserted with the standard technique or a revised method: A comparative study in dry skulls

Corvello PC, Montagner A, Batista FC, Smidt R, Shinkai RS. Length of the drilling holes of zygomatic implants inserted with the standard technique or a revised method: a comparative study in dry skulls. J Craniomaxillofac Surg 2011; 39(2): 119-23.

PMID: 20430638 [PubMed - indexed for MEDLINE]

<http://dx.doi.org/10.1016/j.jcms.2010.03.021>

Journal of Cranio-Maxillofacial Surgery (ISSN: 1010-5182)

The PDF publisher version of this paper is not available in the PUCRS Institutional Repository because this is a RoMEO green journal (Archiving Policy: Can archive preprint and post-print) but author cannot archive publisher's version/PDF.

A versão PDF da editora não está disponível no Repositório Institucional da PUCRS porque este é um periódico classificado como RoMEO verde (Política de Arquivamento: Pode arquivar a versão preprint e postprint), mas o autor não pode arquivar a versão/PDF do editor.

**Length of the drilling holes of zygomatic implants inserted with
the standard technique or a revised method: A comparative
study in dry skulls**

Paula Chiattonne CORVELLO¹

Aline MONTAGNER¹

Felipe Correa BATISTA²

Ricardo SMIDT²

Rosemary Sadami SHINKAI³

¹Graduate Program in Oral Rehabilitation - Implantology, Lutheran University of Brazil, Canoas, RS, Brazil

²Department of Oral Surgery, Lutheran University of Brazil, Canoas, RS, Brazil

³Department of Prosthodontics, Pontifical Catholic University of Rio Grande do Sul, Porto Alegre, RS, Brazil

Corresponding author

Paula Chiattonne Corvello, DDS, MSc

E-mail: pcorvello@yahoo.com.br

SUMMARY

Aim: This study aimed to evaluate the length of the holes drilled for the placing of zygomatic implants using two surgical techniques: the original Brånemark and the Exteriorized (extrasinus) protocols. The most frequent implant length used and position where the implants emerged in the zygomatic bone were recorded.

Materials and Methods: Both surgical techniques for inserting zygomatic implants were performed on the right and left sides of 18 dry adult skulls. The depth of the drilling holes in the zygomatic bone for placement of zygomatic implants and the corresponding implant length were measured. The position where the implant emerged was recorded using a standardized division of the zygomatic bone surface into 13 sections. (Figure 3)

Results: The Exteriorized technique showed significantly longer drilling holes for zygomatic implants than the Brånemark technique ($P<0.001$). For both techniques, the most commonly used implant lengths were 30 and 35 mm, and the most frequent position where the implants emerged were sections 9 and 12.

Conclusions: The results suggest that the Exteriorized technique increases the length of the drilling holes in the zygomatic bone, which may provide higher initial mechanical stability for zygomatic implants than the original Brånemark technique.

Keywords: zygomatic implants; length of the drilling holes; mechanical stability

INTRODUCTION

Severe vertical and horizontal bone resorption in the edentulous maxilla may be caused by a complex interaction of local and systemic factors, such as early tooth loss, periodontal disease, pneumatization of the maxillary sinuses, and tumour resection (*Nkenke et al.*, 2003; *Schmidt et al.*, 2004). Treatment options for the rehabilitation of the severely atrophic maxilla include conventional complete dentures and implant-supported prosthesis with or without sinus augmentation with bone grafts (*Schmidt et al.*, 2004). The clinical decision depends on the patient's local and systemic conditions, personal preferences, and cost. Elderly or medically-compromised patients may not be suitable for bone grafting because of increased surgical risk and morbidity. In these situations, when the surgeon and the patient prefer to avoid surgical reconstruction with autologous bone grafts or when this choice is not available clinically, the use of zygomatic implants is an alternative procedure for treatment of the severely atrophic maxilla (*Hirsch et al.*, 2004; *Aparicio et al.*, 2008 *Ventorri et al.*, 2008).

There still is no consensus on the ideal technique for placing zygomatic implants in relation to the degree of bone anchorage and implant inclination (*Aparicio et al.*, 2008). Little is known about the quantity of zygomatic bone around zygomatic implants placed with different techniques, which could affect initial mechanical implant stability. This in-vivo study in dry skulls aimed to compare the Brånemark technique and the Exteriorized technique in relation to:

- 1) the length of the drilling holes in the zygomatic bone for placement of zygomatic implants;
- 2) the most frequently used zygomatic implant length; and
- 3) the most frequent position where the implants emerged in the zygomatic bone.

MATERIALS AND METHODS

The research protocol was approved by the institutional review board according to national and international standards. Eighteen dry skulls from the Laboratory of Human Anatomy, Lutheran University of Brazil, in Canoas, RS, Brazil, were used. The Brånemark technique (*Brånemark et al.*, 2000) was performed in nine skulls (Figure 1A), while the other nine skulls were subjected to the Exteriorized technique (*Migliorança et al.* 2006) (Figure 1B). Each

surgical technique was performed on the right and left zygomatic bones of the same skull according to anatomical landmarks as follows:

- a) Original Brånemark technique: Firstly, a window was opened in the anterior wall of the maxillary sinus to allow visualization of the zygomatic bone. Perforation of the zygomatic pillar (in the first molar region) was performed with a 2.9mm-diameter cylindrical bur. The implant was placed through the maxillary sinus and emerged palatal to the crestal ridge.
- b) Exteriorized technique: The initial perforation was also performed in the zygomatic pillar (first molar region), but perforation of the zygomatic pillar was performed lateral to the maxillary sinus, leading to the mid-third of the zygomatic implant becoming located outside (ie external to) the maxillary sinus in a vertical position. This results in the implant emerging on the crestal ridge (Figure 2).

To measure the length of the drilling holes for the zygomatic implants in the zygomatic bone, the implant holes were prepared using the 2.9mm-diameter surgical bur from the Zygoma Kit (Nobel Biocare, Göteborg, Sweden). For both techniques the initial perforation in the maxillary ridge was done in the zygomatic pillar. This perforation produced a cylindrical tunnel with a lower bevel (corresponding to the entrance in the zygomatic bone) and an upper bevel (corresponding to the emergence of the preparation in the zygomatic bone) (Figure 2). The length of the drilling holes in the zygomatic bone was measured, in millimetres, from the lower to the upper bevel using a probe supplied with the Zygoma Kit. All measurements were done by one calibrated examiner in duplicate with a one-month interval between measurements (intra-examiner agreement tested by intraclass correlation coefficient test was 0.989). After bone perforations the required implant length was measured using the Zygoma Kit.

To locate the implant emergence site, the zygomatic bone surface was divided into 13 standardized sections according to Rigolizzo *et al.* (Rigolizzo *et al.*, 2005). The zygomatic bone surface was covered by a transparent plastic film, where the 13 sections were numbered, and the emergence site of the implant was recorded (Fig. 3).

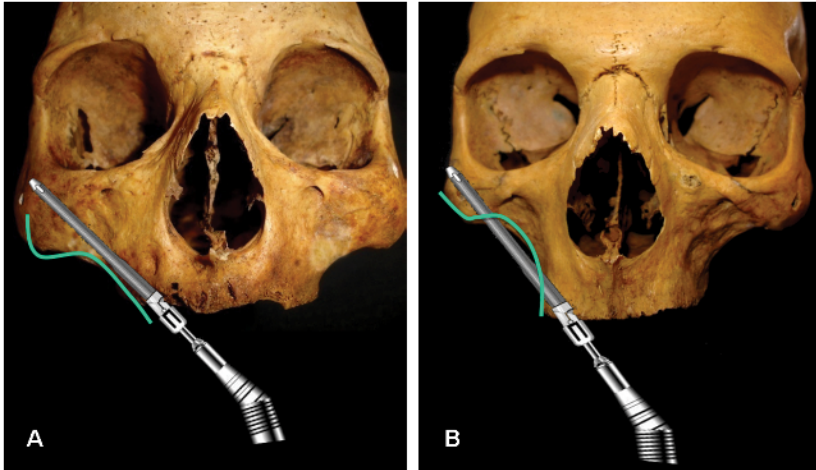


Fig. 1. Scheme of the surgical techniques tested: A) Brånemark technique; B) Exteriorized technique. The green line contours the anatomic concavity of the zygomatic bone used to select the most appropriate surgical technique.

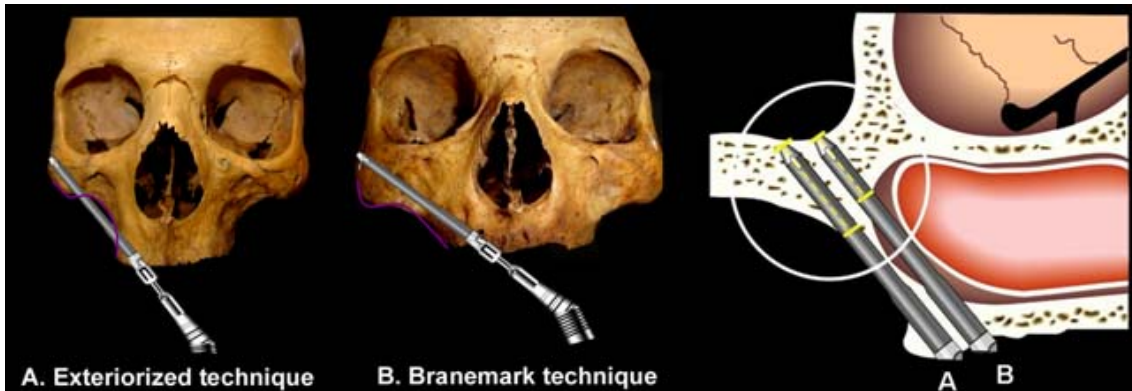


Fig. 2. Schematic presentation of the Exteriorized technique (A) and Brånemark technique (B). A beveled preparation in the zygomatic bone was originated by the cylindrical perforation in both techniques. Length (mm) of implant/length of the drilling holes of was measured from the lower bevel or entrance point to the upper bevel or emergence of the perforation. The Zygoma KIT (Nobel Biocare, Göteborg, Sweden) was used to establish the appropriate length of the zygomatic implant to be placed (30, 35, 40, 45, or 50 mm).

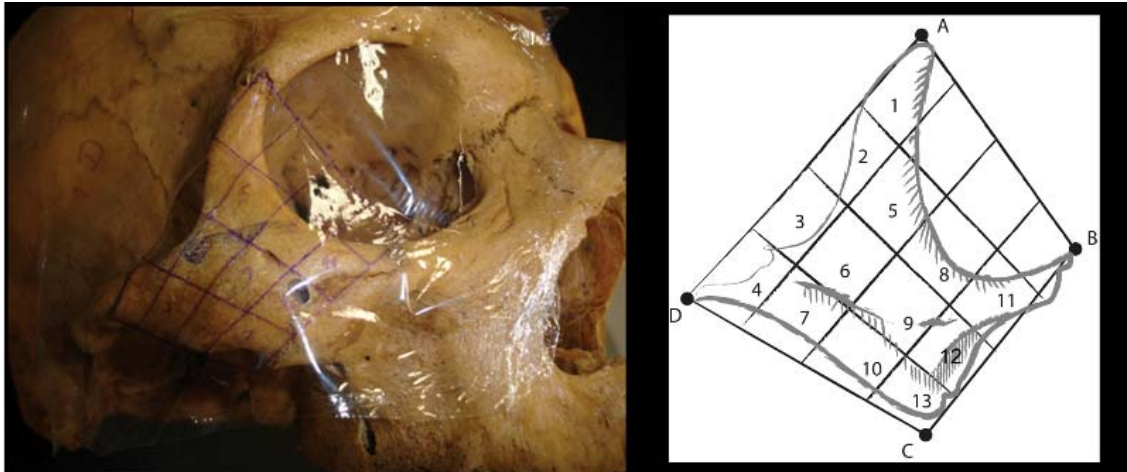


Fig. 3. Zygomatic bone covered by a transparent plastic film divided into 13 sections according to the method proposed by Rigolizzo et al.: The implant perforation emerged in section #12 in this skull. On the right a schematic drawing of the 13 standardized sections to locate the implant emergency site on the zygomatic bone surface.

Data on the length of the drilling holes in the zygomatic bone and implant length (in millimetres) were statistically analyzed by paired Student's t-test at a significance level of 5%. The association between surgical technique and emergency site or implant length was analyzed by Chi-square tests.

RESULTS

The length of the drilling holes in the zygomatic bone varied as a function of surgical technique. The mean value of the Exteriorized technique was significantly higher than that of the original Brånemark technique (Table 1). In relation to implant length, no significant difference was found between the two techniques (Table 1). For both techniques the most commonly used implant lengths were 30 and 35 mm, and zygomatic bone sections 9 and 12 were the commonest positions where the implants emerged (Table 2). There was no association between surgical technique and implant length ($\chi^2=2.38$; $P=0.497$) or the site where the implant emerged ($\chi^2=1.56$; $P=0.670$).

Table 1. Zygomatic implant length and bone contact to implant as a function of surgical technique (Exteriorized *versus* Brånemark).

Outcome Measure	Surgical Technique	n	Mean	SD	P*
Bone contact (mm)	Exteriorized	18	14.11	5.93	<0.001
	Brånemark	18	8.39	2.89	
Implant length (mm)	Exteriorized	18	34.72	4.99	0.199
	Brånemark	18	36.94	5.18	

*Student t-test, 5% significance level.

Table 2. Frequency of implant length and emergency site as a function of surgical technique (Exteriorized *versus* Brånemark).

Outcome measure	Surgical technique	
	Exteriorized	Brånemark
Implant length*		
30mm	7	4
35mm	7	6
40mm	2	5
45mm	2	3
Total	18	18
Emergency site[†]		
Quadrant #5	0	1
Quadrant #8	1	2
Quadrant #9	7	7
Quadrant #12	10	8
Total	18	18

*Implant length ($\chi^2=2.38$; $P=0.497$)

[†]Emergency site ($\chi^2=1.56$; $P=0.670$)

DISCUSSION

This study showed that the Exteriorized technique provided longer holes for zygomatic implant placement in the zygomatic bone than the Brånemark technique, but no difference in implant length was found. In the Exteriorized technique the lateralised placement of the zygomatic implant with the position where the implants emerging in the first molar region provides more penetration of the implant in the zygomatic bone. The Exteriorized technique has fewer surgical steps than the Brånemark and Simplified methods, is less invasive, reduces surgical time, and provides a shorter cantilever as the implant position where the implant emerges is located on the crestal ridge in the first molar region.

Preference for one technique over the other should take into consideration the concavity formed by the ridge crest, maxillary sinus, and region of implant insertion in the zygomatic bone. When the maxilla is severely resorbed, this concavity is small, and the original Brånemark technique should be used. (Fig 1A) On the other hand, when maxillary resorption generates a large concavity, it would be better to exteriorize the zygomatic implant (Fig 1B) (*Migliorança et al.*, 2006).

Although in the original Brånemark technique the zygomatic implant is inserted in the second premolar region, in clinical practice the implant often emerges in the first molar region. (*Pi-Urgell et al.*, 2008). In the present study the initial perforation for both techniques was performed in the alveolar ridge corresponding to the zygomatic pillar with the position where the implants emerge in the first molar region as described in the Simplified (*Stella and Warner*, 2000) and Exteriorized (*Migliorança et al.*, 2006) revisions. This modification was adopted to standardize the initial perforations and allow for comparison of the implant/length of the drilling holes of between the Exteriorized and Brånemark methods, *i.e.*, to indirectly assess the influence of implant inclination and placement inherent to the surgical technique on the length of the drilling holes in the zygomatic bone.

In conventional dental implants initial implant stability derives from mechanical retention between implant surface and bone tissue, and this is also important when using zygomatic implants. Clinical studies have shown good predictability of oral rehabilitation with two or four zygomatic implants (*Bothur et al.*, 2003; *Balshi et al.*, 2003), and the success rate of zygomatic

implants anchored only in zygomatic bone after maxillary tumour resection varies from 65% to 75% (*Weingart et al.*, 1997). When the anchorage occurs in both zygomatic bone and maxillary ridge, the success rate ranges between 82% and 100% (*Bedrossian et al.*, 2000; *Vrielinck et al.*, 2003; *Ferrara and Stella*, 2004; *Hirsch et al.*, 2004; *Galán-Gil et al.*, 2007). In the present study most implants would have bone contact to only one third of the total zygomatic implant length, independently of the surgical technique. This ratio does not seem to represent a clinical problem with sufficient implant fixation in zygomatic and maxillary cortical layers (*Nkenke et al.*, 2003; *Kato et al.*, 2005; *Rigolizzo et al.*, 2005), even when zygomatic implants are placed with a large angulation. There is little experimental or clinical evidence available about the long-term biomechanical effect of implant inclination on bone tissue. Inclined implants provide a larger polygonal area at the position where the implant emerges, which may positively affect load distribution (*Brunski and Skalak*, 2003). Skalak (*Skalak*, 1983) used a mathematical model of a fixed prosthesis supported by three implants to show that axial forces on tilted distal implants decreased in comparison with straight implants. One recent experimental study using strain gauges found that an inclination of distal implants provides better distribution of axial forces and bending moments in fixed prostheses supported by five abutments and reduces the cantilever effect on force magnitude (*Geremia et al.*, 2009). A one-year follow-up clinical study reported 0.9 mm of bone loss around inclined implants in immediately loaded fixed maxillary prostheses supported by four implants (System *All-on-Four*) with two inclined distal implants (*Maló et al.*, 2005). *Krekmanov et al.* (*Krekmanov et al.*, 2000) reported cumulative success rates in the maxilla at 5 years were 98% for tilted implants and 93% for non-tilted implants, whereas *Aparicio et al.* (*Aparicio et al.*, 2001) found that the cumulative success rate was 95.2% (survival: rate 100%) for the tilted implants, 91.3% (survival rate: 96.5%) for the axial implants, and the prosthesis survival rate was 100%, after 5 years. These findings suggest that the use of tilted implants is an effective alternative to more complex surgical procedures, and satisfactory medium-term clinical results show that the technique may allow for longer implants to be placed with improved bone anchorage.

Zygomatic implants are commercially available with length ranging from 30 to 52.5 mm. In the present study, the most used implant lengths were 30 and 35 mm for both techniques. A

recent review of 101 zygomatic implants placed according to the Branemark technique showed that the most frequent implant lengths were 40 and 47.5mm (*Pi-Urgell et al.*, 2008). Differences in the position where the implants emerge (second premolar and first molar) and ethnic characteristics may explain part of these discrepancies.

In relation to the position where the implants emerge on the zygomatic bone surface, in both Exteriorized and Branemark techniques the most frequent positions were 9 and 12, using the method described by Rigolizzo *et al.* (*Rigolizzo et al.*, 2005). These findings are different from the Brånemark System Manual (*Brånemark et al.*, 2000), which reports that sections 5, 6, 8, and 9 have the best potential for the insertion of zygomatic implants. Likewise, Rigolizzo *et al.* (*Rigolizzo et al.*, 2005) evaluated 120 zygomatic bones in dry skulls and showed that regions 5 and 8 were thicker and would be more appropriate for the placement of zygomatic implants. However, Rigolizzo *et al.* (*Rigolizzo et al.*, 2005) did not assess bone quality or consider the pneumatization of the maxillary sinus inside the zygomatic bone.

This in-vivo study has some limitations regarding the methods used to measure implant lengths and locate the position where the implants emerges as the complex tridimensional shapes do not allow strict standardization of dimensions for sections of the zygomatic bone surface, sinuses, and alveolar crests. Nevertheless, the present findings suggest that the Exteriorized technique resulted in an increased length of the drilling holes in the zygomatic bone compared to the original Brånemark technique and may provide better mechanical stability for zygomatic implants. Further biomechanical studies are necessary to see if this longer length of the drilled holes for placement of zygomatic implants provided by the Exteriorized revision is reflected in a gain of implant mechanical stability under loading.

CONCLUSION

Within the limitations of this study, the results suggest that the Exteriorized technique increases the length of the drilling holes in the zygomatic bone, which may provide higher initial mechanical stability for zygomatic implants than the original Brånemark technique.

REFERENCES

- Aparicio C, Perales P, Rangert B. Tilted implants as an alternative to maxillary sinus grafting: a clinical, radiologic, and periotest study. *Clin Implant Dent Relat Res* 1:39-49, 2001.
- Aparicio C, Ouazzani W, Aparicio A, Fortes V, Muela R, Pascual A, Codesal M, Barluenga N, Manresa C, Franch M. Extrasinus zygomatic implants: three year experience from a new surgical approach for patients with pronounced buccal concavities in the edentulous maxilla. *Clin Implant Dent Relat Res* Dec 3 [Epub ahead of print], 2008. DOI 10.1111/j.1708-8208.2008.00130.x
- Balshi TJ, Wolfinger GJ, Petropoulos VC. Quadruple zygomatic implants support for retreatment of resorbed iliac crest bone graft transplant. *Implant Dent* 12:47-53, 2003.
- Bedrossian E, Stumpel L, Beckely M, Indersano T. The zygomatic implant: preliminary data on treatment of severely resorbed maxillae. A clinical report. *Int J Oral Maxillofac Implants* 17:861-865, 2000.
- Bothur S, Jonsson G, Sandahl L. Modified technique using multiple zygomatic implants in reconstruction of the atrophic maxilla: a technical note. *Int J Oral Maxillofac Implants* 18:902-904, 2003.
- Brånemark PI, Engstrand P, Nilsson P, Svensson B, Öhrnell LO. Zygoma fixture clinical procedures. In: Idé SG, Tryck AB (editors) *Brånemark System Manual*. Göteborg, Sweden: Nobel Biocare 4-27, 2000.
- Brunski JB, Skalak R: Biomechanical consideration. In: Worthington P, Brånemark PI. *Advanced osseointegration surgery: application in the maxillofacial region*. Chicago: Quintessence, 15-46, 2003.
- Ferrara ED, Stella JP. Restoration of the edentulous maxilla: the case for the zygomatic implants. *J Oral Maxillofac Surg* 62:1418-1422, 2004.
- Galán-Gil S, Peñarrocha-Diago M, Balaguer-Martínez J, Marti-Bowen E. Rehabilitation of severely resorbed maxillae with zygomatic implants: an update. *Med Oral Patol Oral Cir Bucal* 12:E216-20, 2007.
- Hirsch JM, Öhrnell LO, Henry PJ, Andreasson L, Brånemark PI, Chiapasco M, Gynther G, Finne K, Higuchi KW, Isaksson S, Kahnberg KE, Malevez C, Neukam FW, Sevetz E, Urgell JP, Widmark G, Bolind P. A clinical evaluation of the zygoma fixture: one year of follow-up at 16 clinics. *J Oral Maxillofac Surg* 62(Suppl 2):22-29, 2004.
- Kato Y, Kizu Y, Tonogi M, Ide Y, Yamane G. Internal structure of zygomatic bone related to zygomatic fixture. *J Oral Maxillofac Surg* 63:1325-9, 2005.

Krekmanov L, Kahn M, Rangert B, Lindstrom H. Tilting of posterior mandibular and maxillary implants for improved prosthesis support. *Int J Oral Maxillofac Implants* 15:405-414, 2000.

Maló P, Rangert B, Nobre M. All-on-4 immediate-function concept with Brånemark System implants for completely edentulous maxillae: a 1-year retrospective clinical study. *Clin Implant Dent Relat Res* 7(Suppl 1):88-94, 2005.

Migliorança R, Ilg JP, Serrano AS, Souza RP, Zamperini MS. [Sinus exteriorization of the zygoma fixtures: a new surgical protocol.] *Implant News* 3:30-35, 2006. (in Portuguese)

Geremia T, Naconecy MM, Mezzomo LA, Cervieri A, Shinkai RS. Effect of cantilever length and inclined implants on axial force and bending moment in implant-supported fixed prostheses. *Rev Odonto Cienc* 24:145-150, 2009

Nkenke E, Hahn M, Lell M. *et al.* Anatomic site evaluation of the zygomatic bone for dental implant placement. *Clin Oral Implants Res* 14: 72-79, 2003.

Pi-Urgell J, Revilla-Gutiérrez V, Gay-Escoda C. Rehabilitation of atrophic maxilla: A review of 101 zygomatic implants. *Med Oral Patol Oral Cir Bucal* 13:E363-70, 2008.

Rigolizzo MB, Camilli JA, Francischone CE, Padovani CR, Brånemark PI. Zygomatic bone: anatomic bases for osseointegrated implant anchorage. *Int J Oral Maxillofac Implants* 20: 441-447, 2005.

Schmidt BL, Pogrel MA, Young CW, Sharma A. Reconstruction of extensive maxillary defects using zygomatic implants. *J Oral Maxillofac Surg* 62(Suppl 2): 82-89, 2004.

Skalak R. Biomechanical considerations in osseointegrated prostheses. *J Prosthet Dent* 49:843-848, 1983.

Stella JP, Warner MR. Sinus slot technique for simplification and improved orientation of zygomatic dental implants: a technique note. *Int J Oral Maxillofac Surg* 15:889-893, 2000.

Ventorri D, Corrocher G, Trevisiol L, Scala R, D'Agostino A. The role of zygomatic implants in preprosthetic surgery. *J Craniomaxillofac Surg* 36: 147-148, 2008.

Vrielinck L, Politis C, Schepers S, Pauwels M, Naert I. Image-based planning and clinical validation of zygoma and pterygoid implant placement in patients with severe bone atrophy using customized drill guides. Preliminary results from a prospective clinical follow-up study. *Int J Oral Maxillofac Surg* 32:7-14, 2003.

Weingart D, Schilli W, Strub JR. Präprothetische Chirurgie und Implantologie. *Schweiz Monatsschr Zahnmed* 1992; 102:1075-1081. In: Weischer T, Mohr C. Titanium implants in the zygoma as retaining elements after hemimaxillectomy. *Int J Oral Maxillofac Implants* 12:211-214, 1997.