

Biocompatibility of RealSeal, its primer and AH Plus implanted in subcutaneous connective tissue of rats

Fabiana Soares GRECCA¹, Patrícia Maria Poli KOPPER¹, Régis Burmeister dos SANTOS¹, Anna Christina FOSSATI², Vinicius Coelho CARRARD¹, Gerson Arison Xavier ACASIGUA³, José Antônio Poli de FIGUEIREDO⁴

1- DDS, MSc, PhD, Assistant Professor, Department of Conservative Dentistry, Dental School, Federal University of Rio Grande do Sul, Porto Alegre, RS, Brazil.

2- DDS, MSc, PhD, Associate Professor, Department of Oral Biology, Dental School, Federal University of Rio Grande do Sul, Porto Alegre, RS, Brazil

3- DDS, MSc student, Department of Conservative Dentistry, Dental School, Federal University of Rio Grande do Sul, Porto Alegre, RS, Brazil.

4- DDS, MSc, PhD, Postgraduation Course Coordinator, Pontifical Catholic University, Porto Alegre, RS, Brazil.

Corresponding address: Fabiana Soares Grecca - Avenida Ramiro Barcelos, 2492 - 90035-003 - Porto Alegre, RS - Brazil - Phone/Fax: +55-51-3308-5191 - e-mail: fabiana.grecca@ufrgs.br

Received: May 19, 2009 - Modification: July 15, 2009 - Accepted: August 11, 2009

ABSTRACT

Objective: This study tested rat connective tissue response to RealSeal, RealSeal primer or AH Plus after 7, 15, 30, 60 and 90 days of implantation. Material and methods: Thirty Wistar rats had subcutaneous sockets created on their back and received four implants each of polyethylene tubes containing one of the materials tested according to the groups: AH (AH Plus Sealer); RS (RealSeal Sealer); RP (RealSeal Primer); CG (control group – empty tube). After histological processing, sections were analyzed to identify the presence of neutrophils, lymphocytes and plasma cells, eosinophils, macrophages and giant cells, as well as fibrous capsule and abscesses, by an examiner using light microscope. Kruskal-Wallis and multiple-comparisons test were used for statistical analysis. Significance level was set at 5%. Results: Lymphoplasmacytic infiltrate scores significantly higher than those of the control group were observed at 14 and 60 days in AH group, and at 90 days in RS group ($p < 0.05$). There were no differences in terms of presence of macrophages, giant cells, eosinophils, neutrophils or fibrosis. AH Plus group scored higher for abscesses at 7 days than after any other period ($p = 0.031$). RP group scored higher for lymphoplasmacytic infiltrate at 14 days than at 90 days ($p = 0.04$). Conclusion: The main contribution of this study was to demonstrate that issues involved with tissue tolerance of a Resilon-containing sealer, RealSeal Sealer, cannot be attributed to its primer content.

Key words: Biocompatible materials. Root canal filling materials. Subcutaneous tissue. Endodontics.

INTRODUCTION

Root canal filling is one of the final stages of endodontic treatment. After root canals are filled, clinical and radiographic follow-up should confirm treatment success. Materials used during obturation should meet a number of criteria so that success can be achieved. Of these, biocompatibility is a fundamental property because the filling materials can be placed in close contact with periapical tissues.

The implantation of materials in subcutaneous tissues of rats has been used as a method to study biocompatibility^{4,11,16}. The material under study

may be placed in dentin^{3,5}, silicone^{6,16,17}, Teflon^{7,11} or polyethylene⁹ tubes. When animal testing is applied, material implant in polyethylene tubes has been described as gold standard. Figueiredo, et al.² (2001) did not observe tissue reaction differences compared with sealer sub-mucous injection, but polyethylene tubes helped control the amount of sealer in contact with the tissues.

The materials most frequently used to fill root canals are gutta-percha cones and endodontic sealers. A substitute for gutta-percha cones, RealSeal System (SybronEndo, Sybron Dental Specialties Inc., Orange, CA, USA), uses Resilon cones and RealSeal Sealer (which is basically

Resilon). Previous studies showed lower cytotoxicity levels of Resilon-containing sealers when compared with commonly used sealers^{13,15}. The fact that Resilon has low setting time in anaerobic environment¹⁰ may account to a better tissue response. Also, when associated with good coronal restoration, it seems to display good tissue reaction⁸. However, the literature is scarce as to the biocompatibility of Resilon. Onay, Ozdemir and Ungor¹¹ (2007) tested Resilon marketed as Epiphany, finding good rats' subcutaneous tissue response to this material. However, they have not tested the primer, which is potentially an irritant to the tissues.

Resilon is not the only available resin-containing sealer. A widely used resinous sealer, AH Plus (Dentsply-Maillefer, Tulsa, OK, USA), which is commonly used in conjunction with gutta-percha, has been used as a control for comparison in many tests^{12,14}.

To test the hypothesis that RealSeal and its primer are biocompatible, this study evaluated tissue response to AH Plus, RealSeal or RealSeal primer in polyethylene tubes implanted in subcutaneous connective tissue of rats for 7, 15, 30, 60 and 90 days.

MATERIAL AND METHODS

This study was approved by the Research Ethics Committee of the Dental School of the Federal University of Rio Grande do Sul (UFRGS), Brazil.

Thirty Wistar male rats (*Rattus norvegicus albinus*) weighing 180 to 220 g were obtained from the UFRGS animal care facility. During the study, the animals were kept in routinely cleaned cages at controlled temperature and received water, dry Nuvelab CR1 (Nuvital, Curitiba, PR, Brazil) and Labina (Purina, Campinas, SP, Brazil) chows.

One hundred and twenty polyethylene (nontoxic Scalp Vein 19G) test tubes (1.3 mm inner diameter X 5 mm long) were manufactured. Thirty tubes (AH group) were filled with AH Plus Sealer (Dentsply-Maillefer); 30 (RS group), with RealSeal Sealer (SybronEndo); 30 (RP group) with RealSeal Primer (SybronEndo) and the other 30 (CG - control group) were left empty.

Following preparation of the tubes, the animals received general anesthesia by intramuscular injection of 0.008 mL/100 g ketamine (Francotar™, Virbac do Brasil Indústria e Comércio Ltda., Roseira, SP, Brazil) and 0.004 mL/100 g xylazine chloride 2%

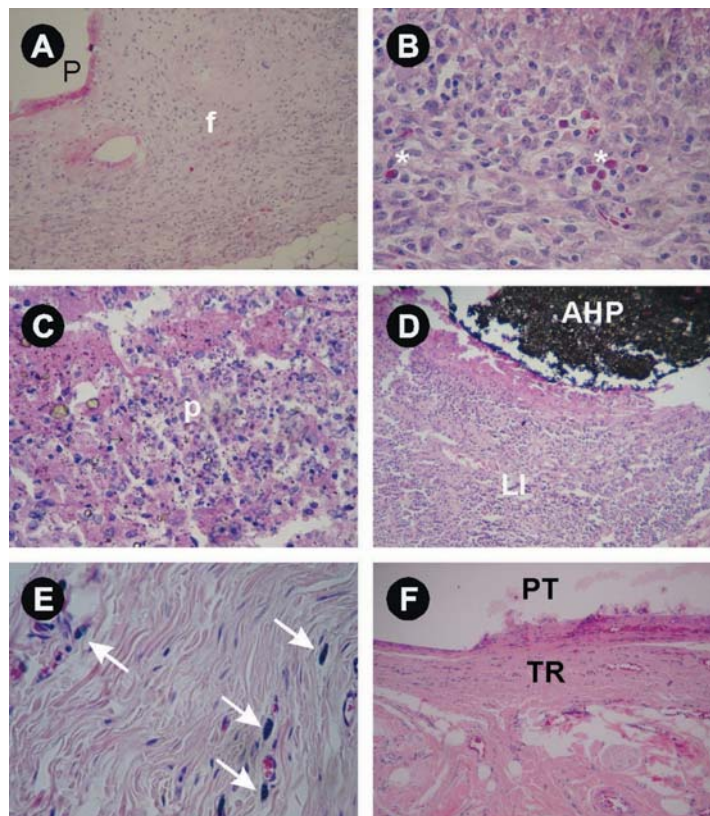


Figure 2- Rat subcutaneous tissue reaction to different materials. A-Thick fibrous connective tissue capsule (f) - Primer(P)/7 days (H&E, Original magnification 100x). B- Mild eosinophils infiltrate (asterisks) - Primer/7 days (H&E, Original magnification 400x). C-Abscess formation (p) - AH Plus (AHP)/7 days (H&E, Original magnification 100x). D- Intense (ou severe) lymphocitic/plasma cells infiltrate (LI)/AH plus 60 days (H&E, Original magnification 100x). E- Macrophages infiltrate (arrows)/Real Seal 60 days (H&E, Original magnification 400x). F- Tissue reaction (TR) to empty polyethylene tubes (PT) implantation (H&E, Original magnification 100x)

Table 1- Mean scores attributed to the AH Plus Sealer (AH), RealSeal Sealer (RS), RealSeal Primer (RP), and Control (CG) groups, after experimental periods of 7, 14, 30, 60 and 90 days, for the six events assessed

Event	Time	Group				p
		AH	RS	RP	CG	
Neutrophils	7 days	11.10	12.00	9.30	7.00	0.390
	14 days	9.50	12.83	9.50	9.50	0.177
	30 days	10.00	10.00	11.67	10.00	0.506
	60 days	13.00	14.17	10.50	10.50	0.282
	90 days	8.00	8.00	10.00	8.00	0.392
Eosinophils	7 days	9.80	8.00	12.00	10.25	0.470
	14 days	9.00	10.58	11.38	11.20	0.742
	30 days	13.75	9.92	8.50	11.13	0.250
	60 days	12.60	15.50	10.00	10.00	0.104
	90 days	8.50	8.50	8.50	8.50	1.000
LPI	7 days	14.30	9.20	8.50	7.50	0.160
	14 days	14.50 ^A	10.00 ^{AB}	12.25 ^{AB}	5.70 ^B	0.049
	30 days	15.38	9.50	9.00	9.38	0.236
	60 days	17.00 ^A	14.75 ^{AB}	9.67 ^{AB}	7.42 ^B	0.030
	90 days	10.50 ^{AB}	12.40 ^A	6.50 ^{AB}	5.40 ^B	0.032
Macr.+ Giant	7 days	12.20	11.90	7.20	8.38	0.354
	14 days	6.80	12.00	12.50	10.80	0.385
	30 days	10.38	8.83	13.58	8.50	0.423
	60 days	11.10	15.75	11.00	10.00	0.384
	90 days	7.50	12.70	5.00	7.50	0.074
Fibrosis	7 days	11.50	7.60	11.50	9.25	0.241
	14 days	12.00	12.00	9.50	8.00	0.215
	30 days	13.50	10.17	11.83	6.00	0.121
	60 days	14.70	13.17	11.25	9.33	0.446
	90 days	11.00	9.40	7.00	7.80	0.591
Abscesses	7 days	13.80	8.00	9.80	8.00	0.079
	14 days	10.50	10.50	10.50	10.50	1.000
	30 days	10.50	10.50	10.50	10.50	1.000
	60 days	12.00	12.00	12.00	12.00	1.000
	90 days	8.50	8.50	8.50	8.50	1.000

p= minimum level of significance of the Kruskal-Wallis non-parametric test

Mean ranks followed by different letters are significantly different according to the Kruskal-Wallis non-parametric test, plus its multiple comparisons test, to a significance level of 5%

(Virbaxyl®, Virbac do Brasil Indústria e Comércio Ltda.). After that, the dorsum of the animals was manually shaved and scrubbed with gauze soaked in 3% alcohol-iodine (Quinta Essência Cosméticos e Medicamento Ltda., Porto Alegre, RS, Brazil).

Four incisions of about 1 cm long and 2 cm distant from each other were made with a #15 scalpel blade (Free-Bac, Embramac Empresa Brasileira de Material Cirúrgico Ltda., Itapira, SP, Brazil) and handle. After each incision, subcutaneous tissue was dissected laterally with blunt-end scissors (Duflex®, SS White Artigos Dentários Ltda., Rio de Janeiro, RJ, Brazil). The surgical pockets were produced on the dorsum of each animal.

A test tube was inserted in each pocket using surgical forceps (Duflex®, SS White Artigos Dentários Ltda., Rio de Janeiro, RJ, Brazil). Each animal received one tube from each experimental group as well as the control. Stratified randomization was used to determine in which pocket the test tube would be inserted, and ensured that the different types of test tubes were inserted in all different positions. After that, the incisions were sutured with 4-0 mononylon stitch (Somerville Ltda., Jabotão dos Guarapes, PE, Brazil).

Six rats were killed at 7, 15, 30, 60, and 90 days postoperatively. The animals were anesthetized again as described above and killed by cervical

dislocation. Immediately after that, excisional biopsies of each implant area were obtained which were immersed in 10% buffered formaldehyde for 48 h.

The samples were embedded in paraffin. A microtome (Leica RM 2025, Nussloch, Baden-Württemberg, Germany) was used to section the blocks to reach the tube. The tube was removed with a dental probe (Duflex®, SS White Artigos Dentários Ltda.), and the block was immersed again in liquid paraffin. After that, the block was sectioned and 5 semi-serial sections 5- to 6- μ m-thick were obtained and then stained with Harris hematoxylin and alcoholic eosin (HE). Results were analyzed by a blinded examiner using a light microscope (BX41TF, Olympus) at 100, 200 and 400x magnifications. The examiner was calibrated before data analysis ($\kappa=0.6$).

For each study sample, only the section that was most representative of the histological condition was chosen. Adjacent tissue in at least one of the tube ends was visualized in every section chosen.

Cell events were classified according to the following scores: 1- absent; 2- mild (sparse cells or very small groups of cells); 3- moderate (cells present but not filling the microscopic field); 4- intense (cell infiltrate).

Fibrous tissue was classified according to the following scores: 1- absent; 2- thin layer of collagen fibers around the material; 3- thick layer of collagen fibers around the material.

Abscesses, characterized by the presence of dead neutrophils (pus) in a large clearly stained area, was classified according to the following scores: 1- absent; 2- abscess in contact with the area that contained the material; 3- abscess also in areas distant from the area that contained the material.

The nonparametric Kruskal-Wallis test was used, and the multiple comparisons test, to determine differences amongst groups. Significance level was set at $\alpha=0.05$.

RESULTS

Some specimens were lost during histological processing, resulting in the following sample distribution according to the experimental periods and groups: 7 days – AH (n=5), RS (n=5), RP (n=5), CG (n=4); 14 days – AH (n=5), RS (n=6), RP (n=4), CG (n=5); 30 days – AH (n=6), RS (n=4), RP (n=4), CG (n=6); 60 days – AH (n=5), RS (n=6), RP (n=6), CG (n=6); and 90 days – AH (n=4), RS (n=5), RP (n=4), CG (n=5).

Figure 1 and Table 1 illustrate the behavior of the groups in terms of the events assessed, at each evaluation period. The groups did not differ significantly from each other in terms of presence of macrophages and giant cells,

eosinophils, neutrophils, fibrosis or abscesses at any of the different experimental periods ($p>0.05$). Lymphoplasmacytic infiltrate scores significantly higher than those of the control group were observed at 14 and 60 days in AH group and at 90 days in RS group.

Comparing the results for each material after different experimental periods, no significant differences were observed in relation to the presence of macrophages and giant cells, eosinophils, neutrophils or fibrosis ($p>0.05$). AH group scored higher for abscesses at 7 days than after any other period ($p=0.031$). RP group scored higher for lymphoplasmacytic infiltrate at 14 days than at 90 days ($p=0.04$).

DISCUSSION

The objective of this study was to conduct an *in vivo* experiment to contribute with regards to the biocompatibility of RealSeal Sealer, comparing it with its own primer, and another resinous sealer (AH Plus).

Tubes containing test materials implanted into the subcutaneous tissue of experimental animals have been employed to test biocompatibility^{3-7,9,11,16-17}. Since this method brings the test substances into contact with connective tissue, it simulates what occurs in the periapical region after obturation of root canals.

Analysis of the results demonstrated that the median score for neutrophils and eosinophils was 1 in all groups, indicating that these cells were absent in the tissue close to the materials. This fact suggests that contact with AH Plus Sealer, RealSeal Sealer and RealSeal Sealer primer are all well-tolerated by the body.

Abscesses were not observed in the primer, RealSeal Sealer or control groups. At 7 days, AH Plus Sealer group exhibited abscesses in contact with the material, and the score after 7 days was significantly higher than for the other periods. Based on this observation, it can be stated that AH Plus Sealer was more aggressive, during the initial period of contact with connective tissue than the other materials.

The results of this investigation are comparable to the findings of Sousa, et al.¹⁴ (2006) and Onay, Ozdemir and Ungor¹¹ (2007), who concluded that Epiphany Sealer, an endodontic sealer with the same chemical composition as that of RealSeal Sealer, is biocompatible. Batista, et al.¹ (2007) also observed that AH Plus Sealer irritated tissues after an initial period (7 days) and that the aggression reduced over time.

CONCLUSION

The main contribution of this study was to demonstrate that issues involved with tissue tolerance of a Resilon-containing sealer, RealSeal Sealer, cannot be attributed to its Primer content. Further studies should be conducted to assess long-term tissue response of these materials, since ageing has not been tested from the biocompatibility point of view.

REFERENCES

- 1- Batista RF, Hidalgo MM, Hernandez L, Consolaro A, Velloso TR, Cuman RK, et al. Microscopic analysis of subcutaneous reactions to endodontic sealer implants in rats. *J Biomed Mater Res A*. 2007;81(1):171-7.
- 2- Figueiredo JA, Pesce HF, Gioso MA, Figueiredo MA. The histological effects of four endodontic sealers implanted in the oral mucosa: submucous injection versus implant in polyethylene tubes. *Int Endod J*. 2001;34(5):377-85.
- 3- Holland R, Souza V, Nery MJ, Bernabé FE, Filho JA, Junior ED, et al. Calcium salts deposition in rat connective tissue after the implantation of calcium hydroxide-containing sealers. *J Endod*. 2002;28(3):173-6.
- 4- Holland R, Souza V, Nery MJ, Faraco IM Jr, Bernabé PF, Otoboni JA Filho, et al. Reaction of rat connective tissue to implanted dentin tube filled with mineral trioxide aggregate, Portland cement or calcium hydroxide. *Braz Dent J*. 2001;12(1):3-8.
- 5- Holland R, Souza V, Nery MJ, Otoboni Filho JA, Bernabé PF, Dezan E Jr. Reaction of rat connective tissue to implanted dentin tubes filled with mineral trioxide aggregate or calcium hydroxide. *J Endod*. 1999;25(3):161-6.
- 6- Kaplan AE, Ormaechea MF, Picca M, Canzobre MC, Ubios AM. Rheological properties and biocompatibility of endodontic sealers. *Int Endod J*. 2003;36(8):527-32.
- 7- Kolokouris I, Economides N, Beltes P, Vlemmas I. *In vivo* comparison of the biocompatibility of two root canal sealers implanted into the subcutaneous connective tissue of rats. *J Endod*. 1998;24(2):82-5.
- 8- Leonardo MR, Barnett F, Debelian GJ, Pontes Lima RK, Bezerra da Silva LA. Root canal adhesive filling in dogs' teeth with or without coronal restoration: a histopathological evaluation. *J Endod*. 2007;33(11):1299-303.
- 9- Molloy D, Goldman M, White RR, Kabani S. Comparative tissue tolerance of a new endodontic sealer. *Oral Surg Oral Med Oral Pathol*. 1992;73(4):490-3.
- 10- Nielsen B, Beeler W, Vy C, Baumgartner J. Setting times of Resilon and other sealers in aerobic and anaerobic environments. *J Endod*. 2003;32(2):130-2.
- 11- Onay EO, Ungor M, Ozdemir BH. *In vivo* evaluation of the biocompatibility of a new resin-based obturation system. *Oral Surg Oral Med Oral Pathol Oral Radiol Endod*. 2007;104(3):e60-6.
- 12- Scarpato RK, Grecca FS, Fachin EV. Analysis of tissue reactions to methacrylate resin-based, epoxy resin-based, and zinc oxide-eugenol endodontic sealers. *J Endod*. 2009;35(2):229-32.
- 13- Scotti R, Tiozzo R, Parisi C, Croce MA, Baldissara P. Biocompatibility of various root canal filling materials *ex vivo*. *Int Endod J*. 2008;41(8):651-7.
- 14- Sousa CJA, Montes CRM, Pascon EA, Loyola AM, Versiani MA. Comparison of the intraosseous biocompatibility of AH Plus, EndoREZ, and Epiphany root canal sealers. *J Endod*. 2006;32(7):656-62.
- 15- Susini G, About I, Tran-Hung L, Camps J. Cytotoxicity of Epiphany and Resilon with a root model. *Int Endod J*. 2006;39(12):940-4.
- 16- Zmener O, Guglielmotti MB, Cabrini RL. Biocompatibility of two calcium hydroxide-based endodontic sealers: a quantitative study in the subcutaneous connective tissue of the rat. *J Endod*. 1988;14(5):229-35.
- 17- Zmener O, Guglielmotti MB, Cabrini RL. Tissue response to an experimental calcium hydroxide-based endodontic sealer: a quantitative study in subcutaneous connective tissue of rat. *Endod Dent Traumatol*. 1990;6(2):66-72.