



Calcified intracavitary mass: a rare presentation of aspergilloma

Edson Marchiori^{1,a}, Bruno Hochhegger^{2,b}, Gláucia Zanetti^{1,c}

A 69-year-old woman presented with a 2-year history of recurrent episodes of hemoptysis, one of which was severe, leading to admission to an intensive care unit. She had a history of pulmonary tuberculosis treated 20 years previously. A chest X-ray (Figures 1A and 1B) and chest CT (Figures 1C and 1D) showed a thin-walled cavity, containing an ovoid calcified mass, in the upper right lobe. The patient underwent right upper lobectomy. Microscopic examination showed that the mass was a calcified capsule filled with abundant necrotic material, fungal hyphae, and birefringent calcium oxalate crystals. Cultures grew *Aspergillus niger*. The final diagnosis was pulmonary aspergilloma caused by *A. niger* and presenting as a calcified mass.

A fungus ball or aspergilloma is the most common cause of intracavitary nodules, generally resulting from fungal colonization of pre-existing lung cavities.⁽¹⁾ One feature of *A. niger* infection that is key for the diagnosis is the presence of calcium oxalate crystals, detected by pathological examination.^(2,3) Some early reports of aspergillomas mentioned calcification, as identified on chest X-rays, which is related to the presence of calcium oxalate crystals. However, to our knowledge, there have been no reports of aspergilloma presenting as a calcified intracavitary mass identified on computed tomography scans.

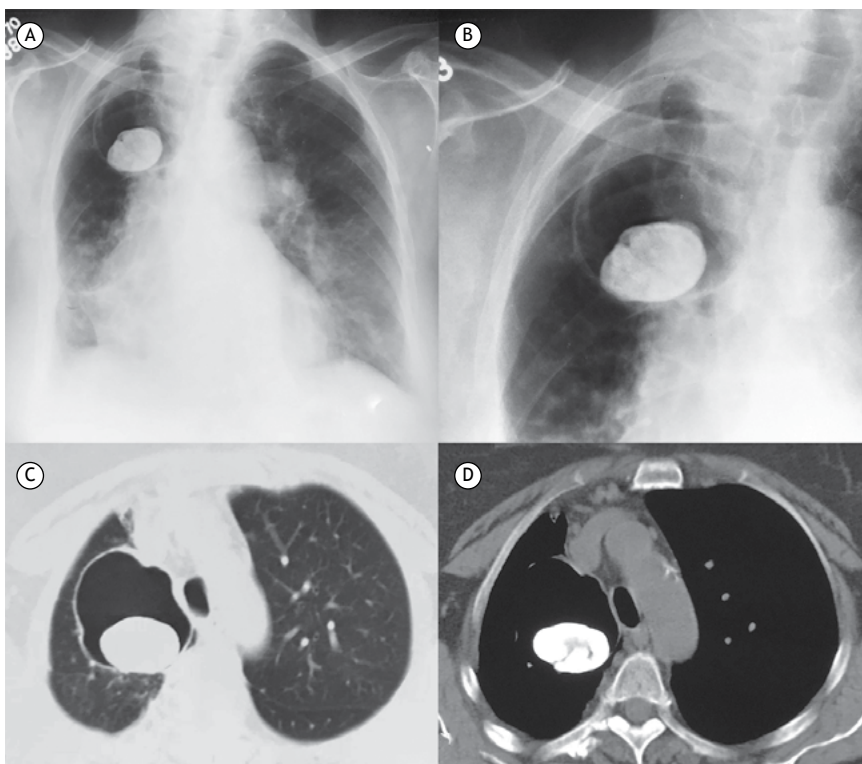


Figure 1. Chest X-ray (A), with a detailed view of the right upper lung region (B), showing a thin-walled cavity in the right upper lobe containing an ovoid calcified mass with a maximum diameter of about 4 cm. Chest CT with lung and mediastinal window settings (C and D, respectively), confirming the presence of the mass inside the cavity.

REFERENCES

1. Marchiori E, Hochhegger B, Zanetti G. Intracavitary nodule. J Bras Pneumol. 2016(5);42:309. <https://doi.org/10.1590/S1806-37562016000000223>
2. Person AK, Chudgar SM, Norton BL, Tong BC, Stout JE. Aspergillus niger: an unusual cause of invasive pulmonary aspergillosis. J Med Microbiol. 2010;59(Pt 7):834-8. <https://doi.org/10.1099/jmm.0.018309-0>
3. Oda M, Saraya T, Wakayama M, Shibuya K, Ogawa Y, Inui T, et al. Calcium oxalate crystal deposition in a patient with Aspergilloma due to *Aspergillus niger*. J Thorac Dis. 2013;5(4):E174-8. <https://doi.org/10.3978/j.issn.2072-1439.2013.08.4>

1. Universidade Federal do Rio de Janeiro, Rio de Janeiro (RJ) Brasil.

2. Universidade Federal de Ciências da Saúde de Porto Alegre, Porto Alegre (RS) Brasil.

a. <http://orcid.org/0000-0001-8797-7380>; b. <http://orcid.org/0000-0003-1984-4636>; c. <http://orcid.org/0000-0003-0261-1860>