



Revista Estomatológica Herediana

ISSN: 1019-4355

ISSN: 2225-7616

Universidad Peruana Cayetano Heredia. Facultad de Estomatología

Cervicofacial actinomycosis: important considerations on a mimicking disease

Mallmann, Lidia; Boff, Renata; Koth, Valesca; Salum, Fernanda; Figueiredo, Maria Antonia; Cherubini, Karen

Cervicofacial actinomycosis: important considerations on a mimicking disease

Revista Estomatológica Herediana, vol. 30, no. 2, 2020

Universidad Peruana Cayetano Heredia. Facultad de Estomatología

Available in: <http://www.redalyc.org/articulo.oa?id=421564337008>

DOI: 10.20453/reh.v30i2.3765

Cervicofacial actinomycosis: important considerations on a mimicking disease

Actinomicosis cervicofacial: consideraciones importantes sobre una enfermedad imitadora

Lídia Mallmann¹

Pontifícia Universidade Católica do Rio Grande do Sul, Brazil

Renata Boff²

Pontifícia Universidade Católica do Rio Grande do Sul, Brazil

Valesca Koth²

Pontifícia Universidade Católica do Rio Grande do Sul, Brazil

Fernanda Salum²

Pontifícia Universidade Católica do Rio Grande do Sul, Brazil

Maria Antonia Figueiredo²

Pontifícia Universidade Católica do Rio Grande do Sul, Brazil

Karen Cherubini²

Pontifícia Universidade Católica do Rio Grande do Sul, Brazil

Revista Estomatológica Herediana, vol. 30, no. 2, 2020

Universidad Peruana Cayetano Heredia.
Facultad de Estomatología

Received: 06 January 2020

Accepted: 13 May 2020

DOI: 10.20453/reh.v30i2.3765

CC BY-NC

SUMMARY: Actinomycosis is a rare chronic suppurative infection that affects upper airways and the gastrointestinal tract. The aim of this work was to review important information regarding the etiopathogenesis, clinical features and treatment of cervicofacial actinomycosis. According to the anatomic site affected, it is classified into three clinical forms: cervicofacial (50%), thoracic (30%) and abdominal (20%). We present here a literature review focusing on important aspects of cervicofacial actinomycosis. Despite the name comprising the term *mycosis*, the disease is caused by Gram-positive bacteria of the genus *Actinomyces*, mainly *Actinomyces israelii*, which are commensals of the oral microbiota. Nevertheless, when the integrity of the oral mucosa is compromised, they can become pathogenic. Actinomycosis evolves slowly and it often mimics other clinical conditions such as malignancies. Treatment consists in antibiotic therapy and can last up to 12 months in severe cases. Health care professionals' knowledge about the disease is crucial in a way to promote its prevention, early diagnosis and proper treatment.

KEY WORDS: cervicofacial actinomycosis, *Actinomyces*, infection.

RESUMEN: La actinomicosis es una enfermedad infecciosa muy infrecuente de tipo crónico y supurativo que afecta al área cervicofacial e el tracto gastrointestinal. El presente trabajo tuvo como objetivo, revisar informaciones importantes en cuanto etiopatogenia, presentación clínica y tratamiento de la actinomicosis cervicofacial. Se puede clasificar de tres maneras a depender del sitio anatómico: cervicofacial (50%), torácica (30%) y abdominal (20%). Presentamos una revisión de la literatura con foco en aspectos importantes de la actinomicosis cervicofacial. Aunque se le denomine *micosis*, la enfermedad es causada por bacterias grampositivas del género *Actinomyces*, siendo que *A. israelii* es el agente etiológico más frecuente, cuales son microorganismos comensales de la boca. Sin embargo, si la integridad de la mucosa es violada, ellos se tornan patogénicos. La actinomicosis es lentamente progresiva y frecuentemente imita otras condiciones clínicas como malignidades. El tratamiento consiste en terapia antibiótica y puede durar 12 meses en casos más graves. El conocimiento de los profesionales de salud acerca

de esa enfermedad es fundamental para promover su prevención, diagnóstico precoz y tratamiento correcto.

PALABRAS CLAVE: actinomicosis cervicofacial, *Actinomyces*, infección.

INTRODUCTION

Actinomycosis is a chronic suppurative infection that affects soft tissues^{1,2}. Cope, in 1938, classified it into three different forms: cervicofacial (50%), thoracic (30%) and abdominal (20%) (3). *Actinomyces*, the etiologic agents of the disease, are anaerobe/microaerophilic, Gram-positive, commensal bacteria, which are found in the oropharynx, gastrointestinal and urogenital tracts^{2,4}. When these microorganisms reach subcutaneous tissues, especially in immunocompromised patients, they become pathogenic¹. The clinical presentation of this infection can be similar to that of tuberculosis and carcinoma, and therefore, actinomycosis can easily be mistaken for these diseases³.

The diagnosis of cervicofacial actinomycosis is often delayed, probably because of its low prevalence and unawareness of health care professionals about the pitfalls involved in the diagnosis process. These professionals, especially physicians and dentists, must be aware of its potential occurrence as well as the therapeutic management of the disease. The aim of this work was to review, in the available scientific literature, important information regarding the etiopathogenesis, clinical features and treatment of cervicofacial actinomycosis.

Etiopathogenesis

Actinomycosis was described in 1848 by Langenback⁵⁾, and in 1878, Israel and Wolf⁶ observed and described the *sulfur granules* in human disease, and defined the anaerobic nature of the microorganism⁷. Originally, it was considered of fungal etiology (mycos), in view of the slow growth and filamentous appearance of *Actinomyces*. Afterwards, it was confirmed that these microorganisms were bacteria⁵. Accordingly, the morphology of *Actinomyces* shows filaments much narrower than fungal hyphae⁶ and bacillary forms as well, and reproduction occurs by binary fission instead of spore formation or budding^{5,6}. Moreover, *Actinomyces* are killed by antibiotics, such as penicillin and erythromycin, but are not affected by antifungal drugs such as amphotericin B⁵.

Actinomycosis is a rare infectious disease caused by various microorganisms of the genus *Actinomyces*, where *Actinomyces israelii* is the main etiologic agent in humans. However, *A. naeslundii*, *A. viscosus*, *A. odontolyticus*, *A. meyeri*, *A. gerencseriae*, *A. pyogenes*, *A. georgiae*, *A. graevenitzii* and *A. neuii* can also be involved in the pathogenesis of the disease^{3,7,8}. Meanwhile, *A. bovis* is known to be the causative agent of actinomycosis in cattle but has never been isolated from humans⁹.

Cervicofacial actinomycosis is the most prevalent form of the disease^{10,11}. *Actinomyces* are part of the normal oral microbiota, where they are commensals of periodontal pockets, caries, dental plaque, calculus and gingival crevices⁶. Nevertheless, they can become pathogenic by accessing the oral submucosa through an *open door*. Mucosal breaks play an important role in providing access to a microaerophilic environment favorable for infection. Therefore, factors such as complication of a maxillofacial trauma after surgical interventions and/or dental interventions in patients showing poor oral hygiene or caries can work as predisposing factors (Figure 1)^{14,12,14}. Actinomycosis occurs almost exclusively by direct invasion, and rarely through hematogenous spread⁶.

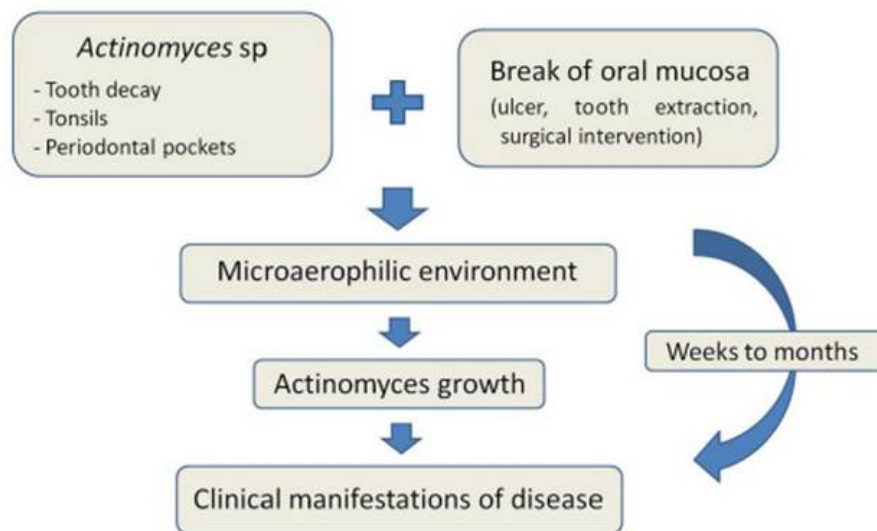


Figure 1

Etiopathogenesis of cervicofacial actinomycosis. *Actinomyces* are commensal microorganisms found in particular sites of oral cavity. Oral mucosa breaks act as an *open door* to a microenvironment favorable for infection, leading to disease onset.

Epidemiology

Actinomycosis is an endogenous, non-contagious and rare infection⁹, which does not have racial predisposition or involvement of geographic factors in its etiopathogenesis¹⁴. However, immunosuppression predisposes to the disease¹⁵. There is slight preference for males, with a male:female ratio of 2.4:1¹¹. Among females, actinomycosis occurs more often between 11 and 30 years of age¹¹, whereas it is rare in the pediatric population¹⁶. Lesions are more prevalent in the perimandibular region and seldom involve bone¹⁷. When accessibility to penicillins was restricted, actinomycosis used to be fatal. During that time, mortality rates of up to 62% were reported¹⁸.

Clinical features

Actinomycosis can occur in three different forms: acute, subacute or chronic⁴. Usually the infection develops silently, showing a solid mass that slowly increases in size and forms many fistulas (Figure 2), which are specific features of the chronic phase¹⁹. The acute phase, however, is less frequent and shows fever, fatigue, malaise and floating edema, reminding an acute dental infection, where pain and trismus can also happen^{6,20}.

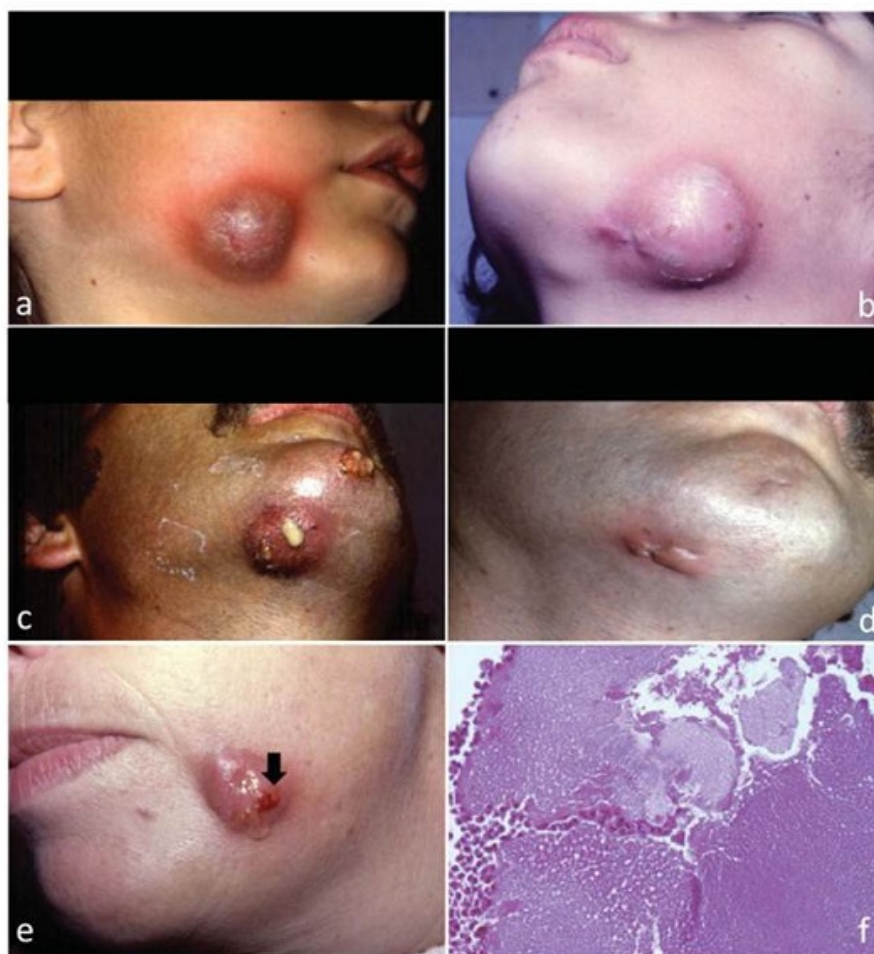

Figure 2

Cervicofacial actinomycosis. Solid mass in mandibular region in a child (a) and in an adult patient (b); the nodule becomes fistulated, with draining pus (c), which can lead to scarring after treatment (d); within the material discharged through the fistulae, it is possible to see the *sulfur granules* (e, arrow) corresponding to the *Actinomyces* colonies (f, HE, 400X).

In most cases, signs and symptoms of infection such as fever, sudden cervicofacial pain, erythema, and edema are absent¹⁴. Initially, the lesions show woody consistency, mimicking neoplasm, but with time, fistulas appear in the region. The nodule then assumes the characteristic multifistulated aspect². There is spread in a contiguous way, regardless of tissue planes, and there is release of bacteria through the fistulas as *sulfur granules*¹⁷. Regional lymphadenopathy is typically absent, also

in more advanced stages ²¹. Cervicofacial actinomycosis can develop in surrounding tissues of any mandibular or maxilla sites. However, the mandibular region is the most frequent site of infection ⁶. Some cases can cause central nervous system (CNS) infection (2%) ¹² by means of direct extension via facial sinuses, orbits, ear canal and perineural (22), where it is possible for the trigeminal ganglion to be involved via the oval foramen ⁵.

Diagnosis

Careful evaluation of the clinical features can lead to a proper diagnosis, which has to consider the presence of *sulfur granules*, as well as the identification of organisms in the examined tissue and positive cultures ¹³. Diagnostic tests include the following: (a) histopathological examination, especially when it mimics other diseases such as primary or metastatic carcinoma ¹³; (b) imaging techniques such as computed tomography (CT) ¹⁴, ultrasonography ¹⁵ and nuclear magnetic resonance, which can help to define the mass characteristics and adjacent soft tissue involvement ¹⁴, where CT can show typical cervicofacial lesions appearing as poorly defined and infiltrative soft tissue masses, which can spread to contiguous spaces, along with the appearance of small necrotic areas ¹³; (c) cytological analysis of fine-needle aspirate, which is the method of choice for the diagnosis of actinomycosis, providing an easy, safe, fast and highly effective method, even though sometimes it might not provide a definitive diagnosis ¹⁴.

Cervicofacial actinomycosis can represent a diagnostic dilemma for clinicians because it can mimic other infectious diseases such as tuberculosis (*scrofula*), abscesses, cysts and neoplasms ^{2,13,17}. Soft tissues often show a woody consistency ^{2,23}, which can lead to a wrong diagnosis of malignancy ^{2,24}. Characteristic lesions develop slowly during weeks to months, giving a bluish or reddish appearance to the region. This presentation is often mistaken for cellulitis, although in fact representing venous congestion. Afterwards, a yellowish-serous exudate containing the characteristic *sulfur granules* drains onto the skin surface or oral mucosa ⁶. The infection can spread directly to the adjacent bones and muscles ²⁵.

Sulfur granules consist of colonies of *Actinomyces* that grossly resemble sulfur grains ¹³. They are yellowish macroscopic structures firm in consistency and visible to the naked eye (figure 2e), varying from 100 to 1000 μm in diameter. Sometimes they can be scarce or absent, requiring many microscopic sections of the sample collected through the fistula or abscess walls to be identified ^{5,6}. Although strongly suggestive of cervicofacial actinomycosis, *sulfur granules* are not pathognomonic, as they can be seen in other diseases such as nocardiosis and chromomycosis ^{2,5,14,26}.

Actinomyces shows filamentous or diptheroidal morphology, where the latter forms seem like non-pathogenic diptheroid *Propionibacteria* and

the thin filaments exhibit V or Y ramifications and bacillary or coccoid forms⁵. Colonies are visible by light microscopy with hematoxylin-eosin (H&E)⁷. Grocott-Gomori-methenamine^{5,7}, methylene-blue, Gram or periodic acid-Schiff staining (PAS)⁵, Methylene-blue, Gram, PAS and Grocott-Gomori staining disclose mycelial ramifications and Gram-positive filaments, which can be mistaken for streptococcus⁵. With conventional methods such as Grocott-Gomori and H&E, it is almost impossible to differentiate *Actinomyces* from *Nocardia* species⁷. Even p-amino-salicylic acid, MacCallen-Goodpasture and Brown-Brenn do not offer any additional sensitivity⁶.

The use of specific conjugated fluorescent antibodies allows rapid and highly specific identification of many species of *Actinomyces* through direct staining even in mixed infections or after formalin fixation^{2,5,7}. The identification of individual filaments within granulation tissue is an advantage of this technique⁷, even though confirmation by means of culture is necessary^{2,5}.

H&E microscopic examination of an excised mass or tissue biopsy can reveal acute or chronic inflammation with loculation of neutrophils, lymphocytes, plasma cells and macrophages as well as dense fibrous connective tissue. Microcolonies are seen as crowded basophilic masses at the center and eosinophilic at periphery with radiating filamentous arms^{15,27}, featuring the *Splendore Hoeppli* phenomenon²⁸. The number of plasma cells increases with lesion chronicity. Fibrosis can be mild in early infections, whereas chronic cases are associated with intense avascular fibrosis, which impairs even more the identification of *Actinomyces* colonies^{5,6}.

Treatment

Cervicofacial actinomycosis treatment requires attention in identifying other pathogens, since the infection tends to be polymicrobial. It is also worth recalling that actinomycosis has a great potential for recurrence and, consequently, may require prolonged treatment¹³. Actinomycetes are sensitive to beta-lactams (penicillin G IV), being these agents the first treatment choice¹⁷. The efficacy of the therapy can be related not only to its direct effect on *Actinomyces israeli*, but also to antimicrobial suppression of the other organisms that are involved in the metabolic ecosystem enabling *Actinomyces* to flourish. These microorganisms include *Actinobacillus actinomycetemcomitans*, *Bacteroides*, *Eikenella*, and *Fusobacterium*⁵.

Penicillin therapy should be intensive, and treatment duration depends on the severity of the case, sometimes lasting as long as 12 months. That is because of the avascular fibrotic walls of the lesions^{19,29,30}, which maintains the anaerobic environment, stimulating the organisms' growth^{11,31}. Depending on disease severity, therapy may consist of high doses of

penicillin G IV (10 to 20 million IU/day) for days or weeks, followed by oral penicillin V (2 to 4 g / day) for 3 to 12 months^{13,17,32-34}.

Actinomyces are in general sensitive to several antibiotics, where penicillin G is the first choice. In case of allergy to it, tetracycline, erythromycin, clindamycin or third-generation cephalosporins can be used^{3,14,35,36}. It is important to point out that metronidazol, aminoglycosides, aztreonam, sulfamethoxazole-trimethoprim, penicillinase-resistant penicillins such as nafcillin and oxacillin, and cephalexin as well are not active against *Actinomyces*^{5,17}.

Surgical intervention may be needed if the response to antibiotic therapy is insufficient^{2,13}, or if there is an extensive area of necrotic tissue or large fistulas². It is sometimes indicated for bone curettage, necrotic tissue resection and drainage of extraoral fistulas. When cervicofacial infection is confined, with low intensity and not associated with drainage fistulas, a clinical approach is preferred instead of surgical interventions^{2,14}. Table 1 summarizes reports in the literature about therapeutic management of cervicofacial actinomycosis.

Table 1
Therapeutic management of cervicofacial actinomycosis

Anatomical site of the lesion (number of cases)	Drug and doses	Duration of treatment (months)	Adjunct treatment	Outcome	Reference
Oronasal (glabrous and alveolar) (n=1)	Amoxicillin 500 mg B/B	3	None	Resolution	Vogel et al. (2)
Parotid (n=1) Submandibular (n=1)	Prophylactic course of penicillin (W/S) High doses of penicillin (W/S)	W/S (W/S)	Partial glossectomy (W/S)	Resolution/Resolution	Shewen et al. (13)
Parotid (n=1)	Amoxicillin/clavulanic acid 2000 mg + 200 mg IV 2x/day 6 days, amoxicillin + clavulanic acid 875 mg + 125 mg 3x/day (1 month)	1-14	Partial glossectomy	Resolution	Lacosta et al. (14)
Cervicofacial (n=1)	Piperacillin/tazobactam 2 g + 0.250 g 3x/day 875 mg and benzathine IV, 4 mg (1 mL/day) 4 days, amoxicillin/clavulanic acid 875 mg + 125 mg 3x/day (1 month)	1-2	Selective neck dissection (right side)	Resolution	Lacosta et al. (14)
Mandibular (n=1)	Amoxicillin/clavulanic acid 875 mg 121 (2)	12	None	Resolution	Smith et al. (17)
Parotid gland (n=1)	Amoxicillin IV 1200 mg 4 days, amoxicillin/clavulanic acid 5 days	0-3	Surgical drainage	Resolution	Sudhakar et al. (22)
Mandibular (n=1), cheek (n=2), buccal (n=2), infraorbital (n=1), infraorbital (n=1), sublingual (n=1), W/S (n=1)	Penicillin G IV 12 million IU 3x/day + ampicillin IV (1-15 days), followed by oral AB or rifampin 2000 mg/day + clindamycin 600mg 3x/day	0.2-4.5	Excision + drainage and debulking if needed (n=14), None (n=7)	Resolution	Majumdar et al. (24)
Parotid (n=1)	Clindamycin penicillin, 2 million IU IV 3x/day (1 month), rifampin 100 mg individual 1x/day 600 mg (6 months)	7	None	Resolution	Edwards et al. (26)
Parotid (n=4)	Penicillin G sodium IV 12 million IU/day (1-5 months), penicillin V oral 1000 mg/day (4-5 months)	6	None	Resolution	Senneker et al. (27)
Submandibular (n=1)	High doses of penicillin (W/S)	1	Surgical excision	Resolution	Vignone et al. (28)

W/S= without other specification; AB=antibiotic therapy

DISCUSSION

Actinomyces israelii is a commensal of the normal oral microbiota, which can become pathogenic if oral mucosal integrity is compromised. It is not possible to anticipate the infection, therefore the decision of prescribing antibiotics before tooth extraction, for example, should not be based on the possibility of the patient developing actinomycosis, which is rather unlikely⁵. Nevertheless, cases of patients showing late infections after dental treatment as well as recurrent infections after short-course antibiotic therapy should be a warning to the dentist about the possibility of the occurrence of cervicofacial actinomycosis^{5,37}. Adequate oral hygiene with proper dental plaque control can prevent the disease, since it impairs the growth of *Actinomyces* in the oral environment⁷.

Besides the possibility of actinomycosis mimicking neoplasms, the reverse process is also possible. That is, there are cases reported in the literature of squamous cell carcinomas misdiagnosed as being

actinomycosis^{40,41}. This is a serious concern, since the late diagnosis of this neoplasm drastically impairs its prognosis⁴⁰.

Although cervicofacial actinomycosis shows low prevalence, it involves significant morbidity and prolonged treatment. In this context, prevention is the best approach, where basic prophylactic procedures and oral hygiene are capable of preventing the disease³⁷. On the other hand, in the case of actinomycosis occurrence, it is important to establish a correct and early diagnosis¹⁷, which demands knowledge about its etiopathogenesis and clinical characteristics. In conclusion, cervicofacial actinomycosis is a rare bacterial infection that evolves slowly and often mimics other clinical conditions such as malignancies. The diagnosis is based on clinical features including the *sulfur granules*, as well as identification of organisms in the examined tissue and positive cultures. Treatment consists in antibiotic therapy and can last up to 12 months in severe cases. Health care professionals' knowledge about the disease is crucial in a way to promote its prevention, early diagnosis and proper treatment.

Acknowledgments

We thank Dr. A. Leyva for English editing of the manuscript.

REFERENCES

1. Göçmen G, Varol A, Göker K, Basa S. Actinomycosis: report of a case with a persistent extraoral sinus tract. *Oral Surg Oral Med Oral Pathol Oral Radiol Endod.* 2011; 112(6): e121-123.
2. Wong VK, Turmezei TD, Weston VC. Actinomycosis. *BMJ.* 2011; 11;343:d6099.
3. Volpi L, Ferreli F, Bignami M, et al. A rare localization of actinomycosis mimicking ulcerative malignancy. *Case Rep Otolaryngol.* 2013;2013:323210.
4. Al-Hezaimi K. Apical actinomycosis: case report. *J Can Dent Assoc.* 2010; 76: a113.
5. Goldberg MH. Diagnosis and treatment of cervicofacial actinomycosis. *Oral Maxillofac Surg Clin North Am.* 2003; 15(1): 51-58.
6. Sharkawy AA. Cervicofacial actinomycosis and mandibular osteomyelitis. *Infect Dis Clin North Am.* 2007; 21(2): 543-556.
7. Walther K, Bruder E, Goldenberger D, Mayr J, Schaad UB, Ritz N. *Actinomyces neuii* Isolated From a 20-Month-Old Girl With Cervical Lymphadenitis. *J Pediatric Infect Dis Soc.* 2015; 4(3):e32-37.
8. Gajdács M, Urbán E, Terhes G. Microbiological and Clinical Aspects of Cervicofacial *Actinomyces* Infections: An Overview. *Dent J.* 2019;1;7(3): E85.
9. Könönen E, Wade WG. *Actinomyces* and related organisms in human infections. *Clin Microbiol Rev.* 2015;28(2):419-442.

10. Weese WC, Smith IM. A study of 57 cases of actinomycosis over a 36-year period. A diagnostic 'failure' with good prognosis after treatment. *Arch Intern Med*. 1975; 135(12):1562-1568.
11. Pulverer G, Schütt-Gerowitt H, Schaal KP. Human cervicofacial actinomycoses: microbiological data for 1997 cases. *Clin Infect Dis*. 2003; 15;37(4):490-497.
12. Lubomski M, Dalglish J, Lee K, Damodaran O, McKew G, Reddel S. Actinomyces cavernous sinus infection: a case and systematic literature review. *Pract Neurol*. 2018;18(5):373-377.
13. Stewart AE, Palma JR, Amsberry JK. Cervicofacial actinomycosis. *Otolaryngol Head Neck Surg*. 2005; 132(6): 957-959.
14. Lancella A, Abbate G, Foscolo AM, Dosdegani R. Two unusual presentations of cervicofacial actinomycosis and review of the literature. *Acta Otorhinolaryngol Ital*. 2008; 28(2): 89-93.
15. Carinci F, Polito J, Pastore A. Pharyngeal actinomycosis: a case report. *Gerodontology*. 2007; 24: 121-123.
16. Foster SV, Demmler GJ, Hawkins EP, Tillman JP. Pediatric cervicofacial actinomycosis. *South Med J*. 1993; 86(10): 1147- 1150.
17. Smith MH, Harms PW, Newton DW, Lebar B, Edwards SP, Aronoff DM. Mandibular actinomyces osteomyelitis complicating fibro-osseous dysplasia: case report. *BMC Oral Health*. 2011; 11: 21.
18. Harvey JC, Cantrell JR, Fisher AM. Actinomycosis: its recognition and treatment. *Ann Intern Med*. 1957; 46:868-885.
19. Daamen N, Johnson JT. Nasopharyngeal actinomycosis: a rare cause of nasal airway obstruction. *Laryngoscope*. 2004; 114(8): 1403-1405.
20. Figueiredo LM, Trindade SC, Sarmiento VA, de Oliveira TF, Muniz WR, Valente RO. Actinomycotic osteomyelitis of the mandible: an unusual case. *Oral Maxillofac Surg*. 2013; 17(4):299-302.
21. Oostman O, Smego RA. Cervicofacial actinomycosis: diagnosis and management. *Curr Infect Dis Rep*. 2005; 7(3): 170-174.
22. Lad SD, Chandy MJ. Cranio-facial actinomycosis. *Br J Neurosurg*. 1991; 5: 361 -370.
23. Sudhakar SS, Ross JJ. Short-term treatment of actinomycosis: two cases and a review. *Clin Infect Dis*. 2004; 38(3): 444-447.
24. Park JK, Lee HK, Ha HK, Choi HY, Choi CG. Cervicofacial actinomycosis: CT and MR imaging findings in seven patients. *Am J Neuroradiol*. 2003; 24(3): 331-335.
25. Lewis MA. A cervicofacial infection due to *Veillonella parvula* in a patient with myxoedema *Br Dent J*. 1989; 166(12):437.
26. Moghimi M, Salentijn E, Debets-Ossenkop Y, Karagozoglu KH, Forouzanfar T. Treatment of Cervicofacial Actinomycosis: a report of 19 cases and review of literature. *Med Oral Patol Oral Cir Bucal*. 2013; 18(4):627-632.
27. Kullar PJ, Yates P. Actinomycosis of the middle ear. *J Laryngol Otol*. 2013; 127(7): 712-715.
28. Pritt B, Mount SL, Cooper K, Blaszyk H. Pseudoactinomycotic radiate granules of the gynaecological tract: review of a diagnostic pitfall. *J Clin Pathol*. 2006; 59(1):17-20.

29. Mullins JE Jr, Ogle O, Cottrell DA. Painless mass in the parotid region. *J Oral Maxillofac Surg*. 2000; 58(3):316-319.
30. Barabás J, Suba Z, Szabó G, Németh Z, Bogdán S, Huszár T. False diagnosis caused by Warthin tumor of the parotid gland combined with actinomycosis. *J Craniofac Surg*. 2003; 14(1): 46-50.
31. Cohn JE, Lentner M, Li H, Nagorsky M. Unilateral Maxillary Sinus Actinomycosis with a closed oroantral fistula. *Case Rep*. 2017;2017:7568390.
32. Moniruddin ABM, Begum H, Nahar K. Actinomycosis: an update. *Medicine today*. 2010; 22(1), 43-47.
33. Elzein F, Kharraz R, Arab N, Alotaibi F, Almohaya A, Almutairy A. A case series of actinomycosis from a single tertiary care center in Saudi Arabia. *IDCases*. 2019; 15: e00521.
34. Brook I. Actinomycosis: diagnosis and management. *South Med J*. 2008; 101(10): 1019-1023.
35. Valour F, Sénéchal A, Dupieux C, et al. Actinomycosis: etiology, clinical features, diagnosis, treatment, and management. *Infect Drug Resist*. 2014; 5;7:183-197.
36. Mark H. Antimicrobial Therapy. In: Gilbert DN, Moellering RC Jr, Sande MA. *The Sanford Guide to Antimicrobial Therapy*. 31st ed. Sperryville, VA: Antimicrobial Therapy Inc; 2010.
37. Dubey A, Murthy JG, Banerjee PK. Actinomycosis of the parotid gland. *Indian J Otolaryngol Head Neck Surg*. 2004;56(4): 306-308.
38. Sittitrai P, Srivanitchapoom C, Pattarasakulchai T, Lekawanavijit S. Actinomycosis presenting as a parotid tumor. *Auris Nasus Larynx*. 2012; 39(2): 241- 243.
39. Volante M, Contucci AM, Fantoni M, Ricci R, Galli J. Cervicofacial actinomycosis: still a difficult differential diagnosis. *Acta Otorhinolaryngol Ital*. 2005; 25(2): 116-119.
40. Raj AT, Patil S. Cervicofacial actinomycosis can obscure a malignancy: A case report. *Oral Oncol*. 2018;80:94.
41. Mokni S, Zerkaa S, Belajouza C, Denguezli M, Nouria R. Oral squamous cell carcinoma of the mandibular region mimicking cervico-facial actinomycosis. *Presse Med*. 2018; S0755-4982(18): 30194-5.

Notes

Financial Disclosure: The authors declare this study has received no financial support or funding

Conflict of interest declaration

Conflict of interest: The authors declare there is no conflict of interest related to this work.