

Pneumopericardium: a rare case of cardiorespiratory arrest

Pneumopericárdio: um caso raro de parada cardiorrespiratória

Cristian Tedesco Tonial¹, Pedro Celiny Ramos Garcia¹, Julia Victora¹,
Caroline Abud Drumond Costa¹, Joanne Sausen Velasques¹, Marcio Abelha Martins²

¹ Pontifícia Universidade Católica do Rio Grande do Sul, Porto Alegre, RS, Brazil.

² Universidade de Santa Cruz do Sul, Santa Cruz do Sul, RS, Brazil.

DOI: [10.31744/einstein_journal/2019AI4516](https://doi.org/10.31744/einstein_journal/2019AI4516)

How to cite this article:

Tonial CT, Garcia PC, Victora J, Costa CA, Velasques JS, Martins MA. Pneumopericardium: a rare case of cardiorespiratory arrest. *einstein* (São Paulo). 2019;17(3):eAI4516. http://dx.doi.org/10.31744/einstein_journal/2019AI4516

Corresponding author:

Cristian Tedesco Tonial
Avenida Ipiranga, 6,690 – Partenon
Zip code: 90610-000 – Porto Alegre, RS, Brazil
Phone: (55 51) 3320-3000 – extension 2218
E-mail: cristiantonial@gmail.com

Received on:

Apr 30, 2018

Accepted on:

Nov 6, 2018

Copyright 2019



This content is licensed under a Creative Commons Attribution 4.0 International License.

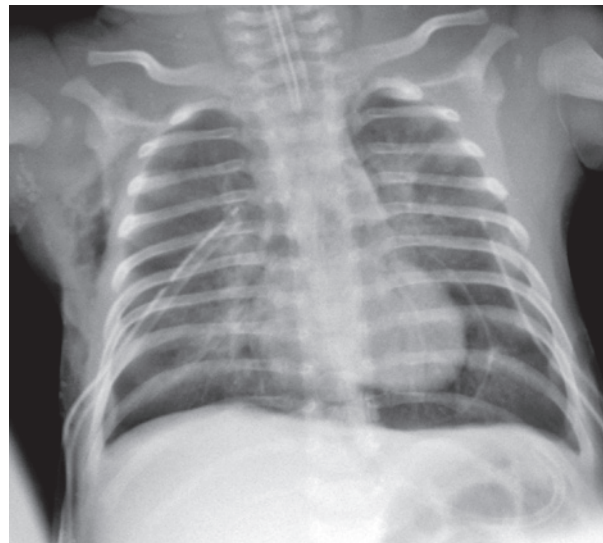


Figure 1. Pneumopericardium

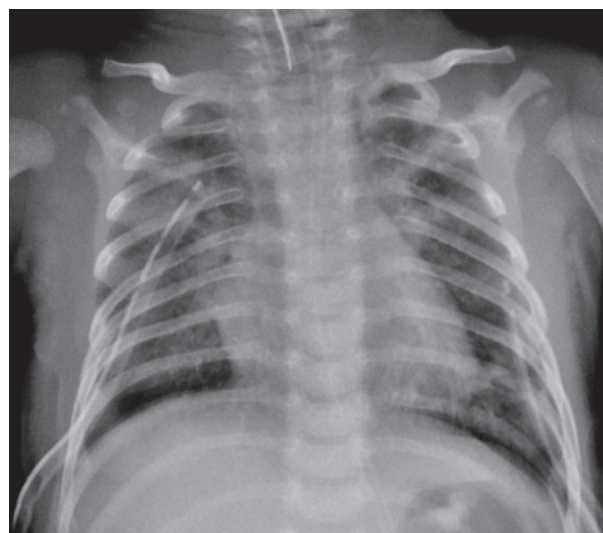


Figure 2. Pneumopericardium drainage after pericardiocentesis

A 37-days-old baby boy, previously healthy and without interurrences during perinatal period, who was admitted in pediatric intensive care unit with acute ventilator insufficiency because of viral bronchiolitis due to respiratory syncytial virus. The patient underwent a tracheal intubation by clinical deterioration, a rapid sequence intubation using fentanyl, ketamine and succinylcholine. During the procedure, he had cough, chest rigidity, reduction of respiratory sounds and poor tissue perfusion. His clinical picture worsened and resulted in cardiorespiratory arrest in asystole that was reverted with chest compressions and two doses of intravenous epinephrine. Subsequently, the patient showed a new cardiorespiratory arrest, and he was under risk for hypertensive pneumothorax. A relief thoracentesis was carried out and significant improvement was observed in respiratory sound and signs of poor peripheral perfusion. After bilateral thoracic drainage the patient had ventilator parameters reduced, however, this reduction remained with impaired tissue perfusion, mottled skin, fine pulses, hypotension, and cardiac auscultation with hypophonesis sound. The chest radiology exam confirmed hypertensive pneumopericardium (Figure 1) that resolved with pericardiocentesis and drainage of 40mL of pericardium air space (Figure 2). The patient had good clinical progress after underwent the procedure, remained in mechanical ventilation for 6 days, and he was discharged 13 days after the procedure without apparent sequelae.

Hypertensive pneumopericardium is a rare condition that can be related with positive-pressure ventilation, laryngeal obstruction, acute or severe asthma or closed chest trauma.⁽¹⁾ Mortality rates can reach 80% in neonates.^(2,3) This condition has a clinical feature of cardiac tamponade and a differential diagnosis is pneumothorax.⁽³⁾ Premature patients with hyaline

membrane disease who underwent mechanical ventilation are at higher risk for this disease, however, reports exist on spontaneous pneumopericardium in healthy infants, and in those who develop bronchiolitis by respiratory syncytial virus.^(4,5) In this case, although epinefrin administration have promoted temporary circulation support, the rapid diagnosis and resolution of the cardiac tamponade via pericardiocentesis contributed to the good evolution of the patient.⁽⁶⁾

AUTHORS' INFORMATION

Tonial CT: <http://orcid.org/0000-0001-6643-2090>

Garcia PC: <http://orcid.org/0000-0002-1863-0727>

Victora J: <http://orcid.org/0000-0001-6536-6300>

Costa CA: <http://orcid.org/0000-0002-9715-0579>

Velasques JS: <http://orcid.org/0000-0002-0548-3422>

Martins MA: <http://orcid.org/0000-0002-6222-3387>

REFERENCES

1. el Gamel A, Barrett P, Kopff G. Pneumopericardium: a rare cause of cardiac tamponade in an infant on a positive pressure ventilation. *Acta Paediatr.* 1994;83(11):1220-1.
2. Kyle A, Veldtman G, Stanton M, Weeden D, Baral V. Barotrauma-associated posterior tension pneumomediastinum, a rare cause of cardiac tamponade in a ventilated neonate: a case report and review of the literature. *Acta Paediatr.* 2012;101(3):e142-4.
3. Neal MD, Hackam DJ. Tension pneumopericardium in an infant. *Surgery.* 2011;149(3):457-8.
4. Suresh P, Tagare A, Kadam S, Vaidya U, Pandit A. Spontaneous pneumopericardium in a healthy full-term neonate. *Indian J Pediatr.* 2011;78(11):1410-1.
5. Fantacci C, Ferrara P, Franceschi F, Chiaretti A. Pneumopericardium, pneumomediastinum, and pneumorrhachis complicating acute respiratory syncytial virus bronchiolitis in children. *Eur Rev Med Pharmacol Sci.* 2017; 21(15):3465-8.
6. Levin AI, Visser F, Mattheyse F, Coetzee A. Tension pneumopericardium during positive-pressure ventilation leading to cardiac arrest. *J Cardiothorac Vasc Anesth.* 2008;22(6):879-82.