

See discussions, stats, and author profiles for this publication at: <https://www.researchgate.net/publication/354685025>

Surgical Orthodontic Treatment in a Class III Patient with Transversal, Sagittal and Vertical Skeletal Discrepancy: Case Report with 3–Years Follow-up

Article · August 2021

CITATIONS

0

READS

216

5 authors, including:



Susana Maria Deon Rizzato

Pontifícia Universidade Católica do Rio Grande do Sul

72 PUBLICATIONS 477 CITATIONS

[SEE PROFILE](#)



Betina Behs

Pontifícia Universidade Católica do Rio Grande do Sul

2 PUBLICATIONS 0 CITATIONS

[SEE PROFILE](#)



Rogério Belle de Oliveira

Pontifícia Universidade Católica do Rio Grande do Sul

71 PUBLICATIONS 893 CITATIONS

[SEE PROFILE](#)



Luciane M Menezes

Pontifícia Universidade Católica do Rio Grande do Sul

173 PUBLICATIONS 1,854 CITATIONS

[SEE PROFILE](#)

Some of the authors of this publication are also working on these related projects:



Oral and Maxillofacial Pathology - Surgical Interventions [View project](#)



Curso de especialização de ortodontia PUCRS [View project](#)



Surgical Orthodontic Treatment in a Class III Patient with Transversal, Sagittal and Vertical Skeletal Discrepancy: Case Report with 3-Years Follow-up

Susana Maria Deon Rizzato, Betina Saldini Behs*, Rogério Belle de Oliveira, Luciane Macedo de Menezes and Eduardo Martinelli de Lima

Department of Dentistry, School of Health and Life Sciences, Pontifical Catholic University of Rio Grande do Sul (PUCRS), Brazil

Abstract

Introduction: This case report describes the surgical orthodontic treatment of a Class III young adult patient with transversal, sagittal and vertical skeletal discrepancy.

Case Report: A male at age of 18 years sought treatment due to poor dentofacial aesthetics. He had a hyperdivergent face, skeletal Class III, mandibular prognathism, maxillary retrognathism, transverse deficiency, and dental crowding in both jaws.

Treatment Progress: Orthodontic first stage decompensated the mandibular posterior teeth lingually inclined, and aligned maxillary molars and premolars. First surgery performed Le Fort I osteotomy to Surgical Assisted Rapid Maxillary Expansion (SARME). A second orthodontic stage created a negative overjet through proclination of mandibular incisors. Double-jaw surgery performed Le Fort I osteotomy with maxillary advancement (5 mm) and impaction (4 mm), and Bilateral Sagittal Split Osteotomy (BSSO) with mandibular setback (3 mm). A third orthodontic stage achieved detailing of the occlusion.

Treatment Results: At the treatment end, the patient showed improvement of dentofacial aesthetics, maxillary and mandibular teeth well aligned in dental arches with compatible form, proper intercuspation of posterior teeth, normal inter-incisors relationship, and normal function. The 3-years follow-up indicated treatment stability in short-term.

Conclusion: Surgical orthodontic treatment with individualized sequence achieved successful results in a Class III young adult with transversal, sagittal, and vertical skeletal discrepancy.

Keywords: Dentofacial deformity; Orthognathic surgery; SARME; Skeletal Class III

Introduction

Class III patients show a wide range of variation in dentofacial features, as result of the interaction between genetic and environment factors. Long face patients may have maxillary retrognathism and/or mandible prognathism [1,2]. Nevertheless, poor facial aesthetics is the most common chief complaint of the Class III patients [3]. Combined surgical orthodontic treatment is a common therapy for skeletal Class III patients, because it is effective and predictable [3-5]. Presurgical orthodontics aims alignment, leveling and decompensation of the teeth and establishes compatible dental arch forms. Main surgical techniques used for Class III patients are the Le Fort I osteotomy and mandibular Bilateral Sagittal Split Osteotomy (BSSO). The patients with a transverse deficiency of the maxilla may need first stage surgically assisted rapid maxillary expansion (SARME) [4-7]. A short orthodontic phase after surgery, allows the detailing of the occlusion [3-5]. Aesthetic and functional outcomes of surgical orthodontic treatments depend on the diagnosis accuracy, individualized treatment plan and team skills [3]. Nevertheless, patient compliance is essential to treatment success. This case report describes the treatment of a Class III young adult, which was performed with three orthodontic phases and two surgical times. The patient signed an informed consent form, before enrollment.

Case Description and Diagnosis

An eighteen years old male sought treatment with the chief complaint of poor dentofacial aesthetics. He reported a previous surgery to reduce a maxillary fracture caused by a bicycle

OPEN ACCESS

*Correspondence:

Betina Saldini Behs, Department of Dentistry, School of Health and Life Sciences Pontifical Catholic University of Rio Grande do Sul (PUCRS), Ipiranga Av. 6681 – Building 6, Room 410, Zip: 90619-900, Brazil, Tel: + 55 51 3320-3538;

E-mail: betinabehs@gmail.com

Received Date: 20 Jul 2021

Accepted Date: 20 Aug 2021

Published Date: 24 Aug 2021

Citation:

Rizzato SMD, Behs BS, de Oliveira RB, de Menezes LM, de Lima EM. Surgical Orthodontic Treatment in a Class III Patient with Transversal, Sagittal and Vertical Skeletal Discrepancy: Case Report with 3-Years Follow-up. Clin Surg. 2021; 6: 3291.

Copyright © 2021 Betina Saldini Behs. This is an open access article distributed under the Creative Commons Attribution License, which permits unrestricted use, distribution, and reproduction in any medium, provided the original work is properly cited.

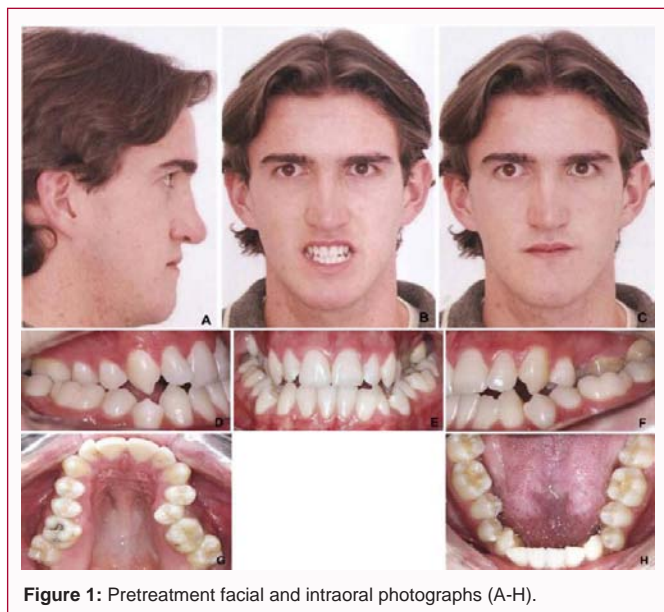


Figure 1: Pretreatment facial and intraoral photographs (A-H).

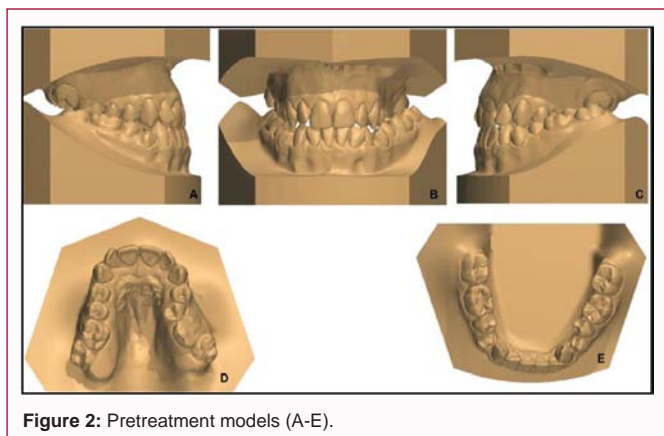


Figure 2: Pretreatment models (A-E).

accident at the age of fifteen. The patient had a hyperdivergent and symmetric face, large mandible with steepen mandibular plane, medium facial third deficiency, concave profile and no passive sealing of the lips. His smile exhibited a narrow maxillary dental arch and crowded upper and lower teeth. Intraoral photographs show a Class III occlusion, edge-to-edge incisors bite and bilateral posterior cross bite. Mandibular dental midline is slightly deviated to the left. Arch length discrepancy was -8 mm in both jaws. The transverse deficiency of the maxilla was of 9 mm, in the first molars region (Figure 1, 2). Pretreatment panoramic X-ray revealed old fracture fixation plates in the maxilla, a crown lesion in the upper left first molar and absence of all third molars. Cephalometric analysis indicated a skeletal Class III (ANB -8°; Angle of convexity -20°; Unit Difference 49 mm; Wits - 18 mm), with high-angle mandibular plane (GoGn.SN 39°; FMA 39°), maxillary retrognathism (SNA 78°; Co-Sn 71 mm), mandibular prognathism (SNB 86°; Facial Angle 91°), and concave profile (S-Ls - 4 mm; S-Li - 7 mm). Maxillary incisors were protruded (1.NA 36°; 1-NA 10 mm) and mandibular incisors were inclined backwards (IMPA 63°) (Figure 3 and Table 1). Treatment objectives were to improve dentofacial esthetics; correct the transversal, sagittal and vertical skeletal discrepancy; decrease the lower anterior facial height; correct dental crowding; align the maxillary and mandibular teeth properly in dental arches with compatible form; level the curve of Spee; achieve a normal occlusion with Class I relationships, normal overjet,

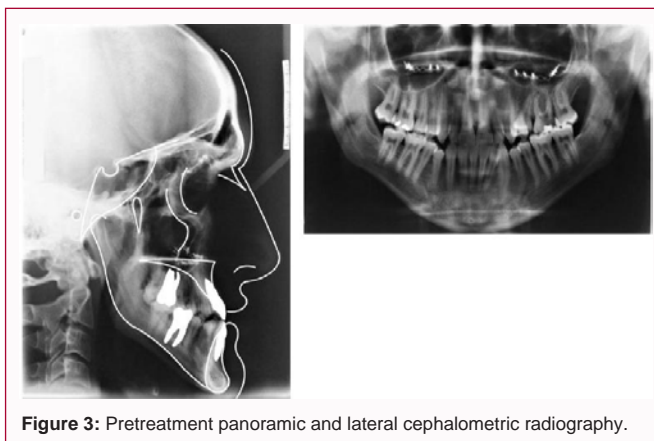


Figure 3: Pretreatment panoramic and lateral cephalometric radiography.

Table 1: Cephalometrics.

Measurement	Norm	Pretreatment	Post treatment	Difference
SNA (°)	82	78	81	3
SNB (°)	80	86	85	-1
ANB (°)	2	-8	-4	4
1.NA (°)	22	35	32	-3
1-NA (mm)	4	12	11	-1
1.NB (°)	25	9	19	10
1-NB (mm)	4	1	3	2
S-Ls (mm)	0	-4	-5	-1
S-Li (mm)	0	-7	-5	2
GoGn.SN (°)	32	39	33	-6
FMA (°)	25	39	33	-6
IMPA (°)	90	61	78	17
Facial angle (°)	87	91	92	1
Angle convexity (°)	0	-20	-16	4
Y-axis (°)	57	62	59	-3
Wits (mm)	0	-18	-4	14
Co-Sn (mm)	99	71	77	6
Co-Gn (mm)	125	120	120	0
Unit Diff (mm)	26	49	43	-6

and normal overbite; and establish normal function. Orthodontic camouflage was discarded, due to the large skeletal discrepancy in the transversal, sagittal, and vertical dimensions. A single-jaw surgery was not sufficient treatment for such a retrognathic maxilla and large mandible. A large mandibular setback could trigger obstructive sleep apnea [8]. Maxillary segmental surgery for correction of the transversal, sagittal and vertical discrepancies caused concern on treatment stability in long-term. Besides, removing the old and replacing for new plates in the same surgery had a higher risk of bone fracture in areas of low-density bone [9,10].

Treatment Progress

The objectives of orthodontic first stage were the correction of the lingual inclination of mandibular molars and premolars, to reveal the actual maxillary expansion required and alignment of maxillary posterior teeth, to eliminate undesired occlusal contacts during SARME. Fixed appliances 0.022 × 0.028-inches were mounted, alignment and leveling was performed with a sequence of Nickel-

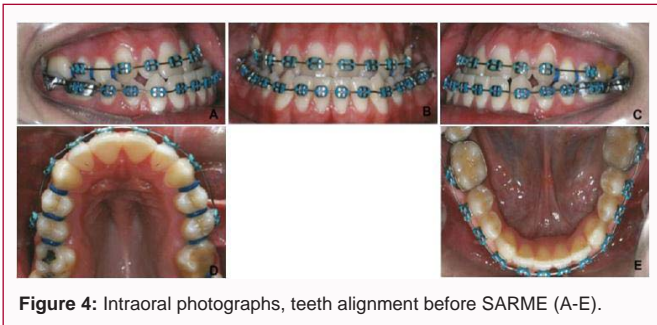


Figure 4: Intraoral photographs, teeth alignment before SARME (A-E).

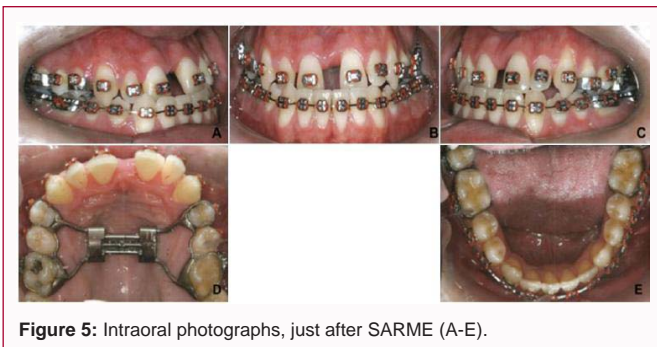

Figure 5: Intraoral photographs, just after SARME (A-E).

Titanium (Ni-Ti) and Stainless Steel (SS) archwires. Separating elastics were placed between maxillary posterior teeth of both sides, and replaced every other week, in order to create spaces for their alignment (Figure 4). As soon as initial alignment of the maxillary and mandibular teeth was achieved, a four-band Hyrax expander was cemented. The first surgery removed the old maxillary fixation plates and performed a Le Fort I osteotomy to release the maxillary bone. SARME started after 7 days, with the activation protocol of ¼ turn in the screw, 12/12 h, for 21 days. The Hyrax expander remained in place for additional 6 months, as retention for bone formation in the mid-palatal suture (Figure 5). The forces system design of the second orthodontic phase created forward resultant forces, with the objective of proclination of mandibular incisors. The maxillary median diastema was closed with sliding mechanics and elastomeric chains. Stabilization archwires SS 0.020 × 0.025 inches were placed in the maxilla and in the mandible two months before second surgery. The negative overjet achieved at the end of this phase allowed surgical correction of 8 mm in the sagittal plane. The double-jaw surgery performed Le Fort I osteotomy with maxillary advancement of 5 mm combined with maxillary impaction of 4 mm. Forward mandibular self-rotation followed maxillary impaction. BSSO was performed with 3 mm mandibular setback. Surgical fixation relied on titanium miniplates, in the maxilla and in the mandible. Class III intermaxillary elastics were used full time for three months to prevent postsurgical relapse. The third orthodontic phase had the objectives of finishing and detailing of the occlusion. The retention was a lingual bar bonded to mandibular canines, a bar bonded to maxillary central incisors and a maxillary wraparound acrylic plate, used full time for 12 months and nighttime afterwards. Total treatment time was 48 months, plus a 12 months period between the two surgeries required by Public Health Care.

Treatment Results

Outcomes of treatment showed a definite improvement in the patient’s dentofacial aesthetics. The maxillary prominence was in proportional balance with the chin. The profile became harmonic

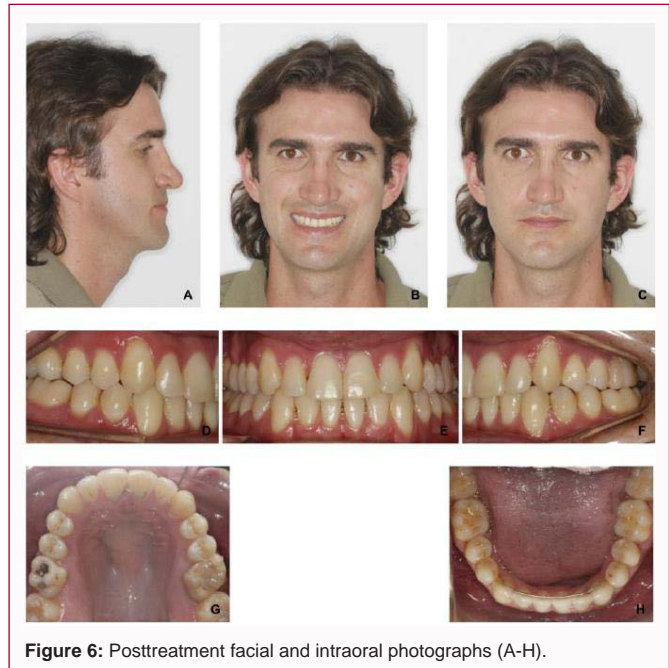


Figure 6: Posttreatment facial and intraoral photographs (A-H).

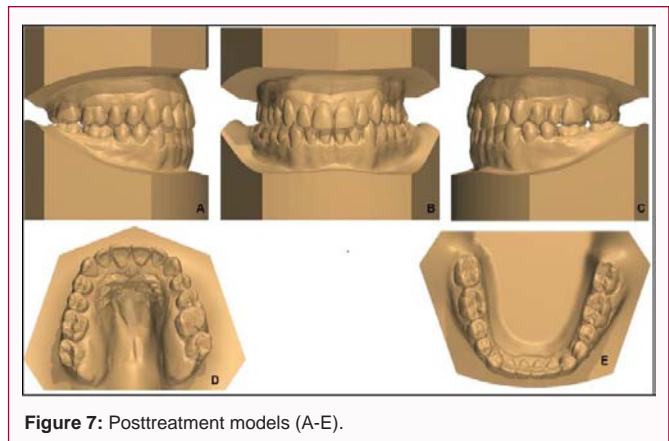


Figure 7: Posttreatment models (A-E).

due to upper and lower lips of same volume and with a passive sealing. The smile displayed a wide maxillary dental arch and upper teeth in close relationship with lower lip curvature. Maxillary and mandibular teeth were well aligned, and leveled, in dental arches with compatible forms. In the maxilla, the intercanines distance increased 5 mm and intermolars distance increased 12 mm. In the mandible, the intercanines distance increased 6 mm and intermolars distance increased 3 mm. The occlusion had Class I relationships, normal overjet, normal overbite and proper function (Figure 6, 7). The final panoramic X-ray revealed the bone fixation plates in the maxilla and in the mandible, a retention device in the lower anterior teeth, another in the upper central incisors and root-filled upper left first molar. Cephalometric analysis indicated that the surgical orthodontic treatment improved skeletal relationships, in the sagittal plane (ANB +4°; Angle of convexity +4°; Wits +14 mm), and in the vertical plane (GoGn.SN -6°; FMA -6°; y-axis -3°). The soft tissue changes created harmony in the concave profile (S-Ls - 5 mm; S-Li - 5 mm) (Figure 8 and Table 1). The large proclination of mandibular incisors (IMPA 17°; 1.NB 10°; 1-NB 2 mm) was within the limits of the mandibular symphysis morphology, whereas maxillary incisors retrusion was minimal (1.NA -3°; 1-NA - 1 mm). Superimposition of pre and post treatment cephalograms showed maxillary advancement (5 mm)

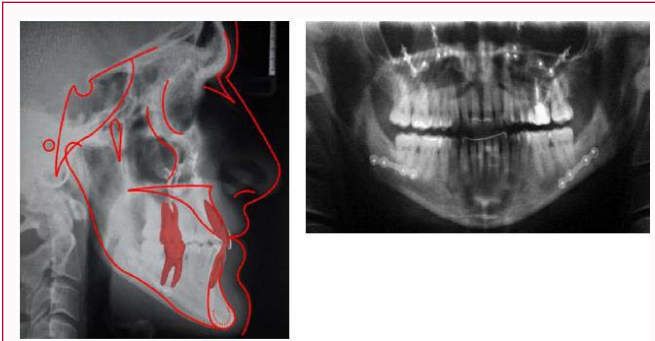


Figure 8: Posttreatment panoramic and lateral cephalometric radiography.

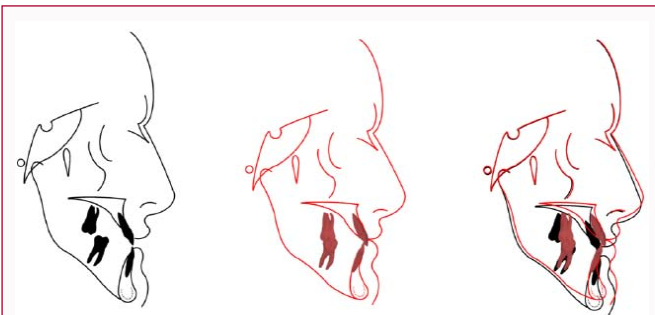


Figure 9: Cephalograms, pretreatment (black), post treatment (red), and superimposition.

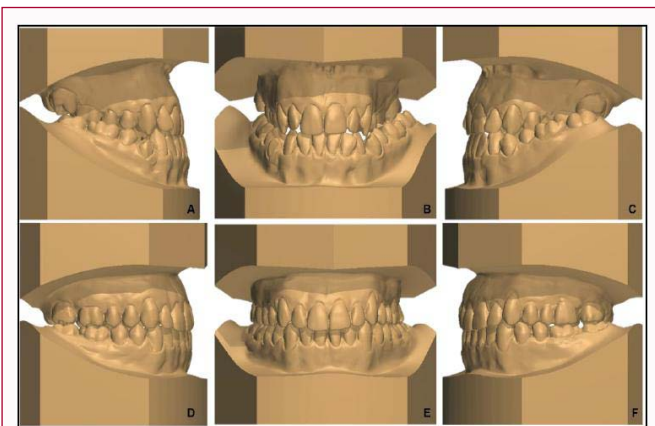


Figure 10: Pre (A-C) and post treatment (D-F) comparison models.

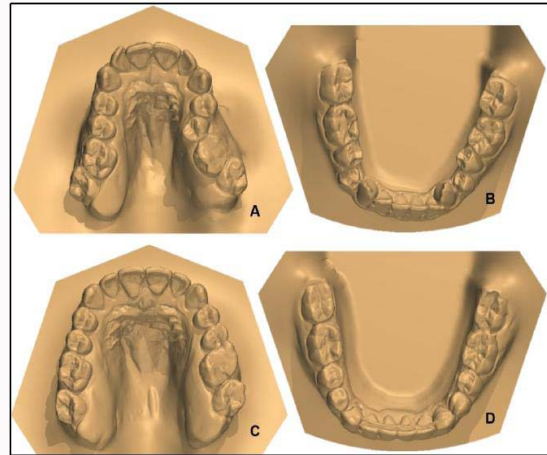


Figure 11: Pre (A-B) and post treatment (C-D) comparison models.

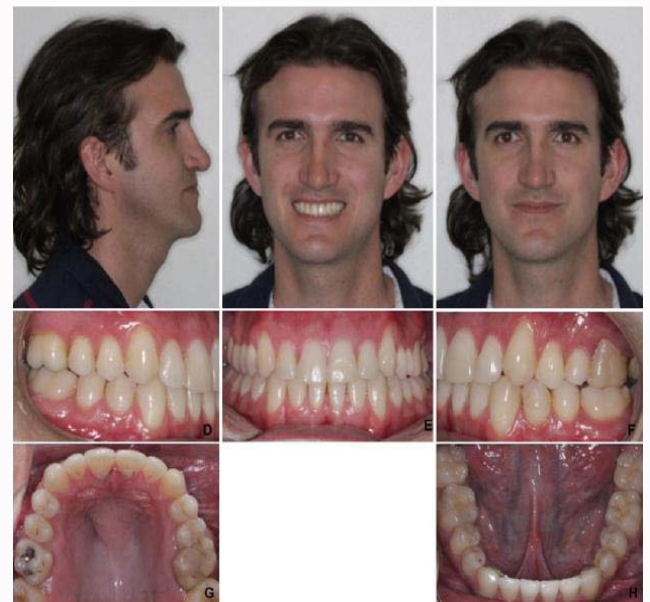


Figure 12: Three-year follow-up facial and intraoral photographs.

and maxillary impaction (4 mm), forward mandibular self-rotation, mandibular setback (3 mm), and proclination of mandibular incisors (Figure 9). The comparison of the pre and post treatment models shows the results in the transversal and sagittal plans (Figure 10, 11). The 3-year follow-up indicated stability of treatment results in short-term. The patient showed a face with balance and harmony, despite of the prominent chin. His smile displayed the maxillary teeth in harmonic relationship with the lower lip curvature. The occlusion showed proper intercuspation of the posterior teeth, normal interincisors relationship and no mandibular shift (Figure 12). The patient stated the outcomes of treatment overcame his expectations, in terms of dentofacial aesthetics and oral-health related quality of life.

Discussion

The individualized treatment plan, following three orthodontic phases and two surgical times, fulfilled the patient’s needs in

terms of aesthetics and function. The orthodontic first stage was performed with two-fold objectives: at first, the correction of the lingual inclination of mandibular posterior teeth revealed the actual maxillary expansion required. Secondly, the alignment of maxillary molars and premolars eliminated undesired occlusal contacts and favored symmetric SARME. Maxillary dental arch width was one of the keys for treatment success. Choice of SARME, instead of segmental maxillary surgery, took in account long-term stability and changes needed in the transversal, sagittal and vertical plane. Besides, removing the old maxillary plates in the first surgery was safer than removing old and replacing for new plates in a same surgery. SARME allowed an increase of 5 mm in the maxillary intercanines’ distance, similar to that reported in other study [7]. The 12 mm increase in the intermolars distance resulted of both, orthodontic expansion and SARME. Proclination of mandibular incisors, in the second orthodontic stage, was performed under the limits of a thin mandibular symphysis. The negative overjet of 8mm achieved was a limitation for the surgical correction of the sagittal skeletal discrepancy [11]. Double-jaw surgery results were predictable. Le

Fort I osteotomy for maxillary advancement increased the SNA (3°) and Co-Sn (6 mm), and established a prominent mid- facial third. Maxillary impaction was responsible for the outcomes of treatment in the vertical plane. Forward mandibular self-rotation (GoGn.SN - 6°; FMA - 6°) caused favorable soft tissue changes and improved the facial profile. Nevertheless, forward mandibular self-rotation worked against correction of the sagittal skeletal discrepancy. Despite of BSSO and mandibular setback, the Facial Angle increased (1°) and SNB showed a slight decrease (-1°). Zygomaticomaxillary prominence was the counterpart for a prominent chin [12,13]. Detailing of the occlusion may have a role in stability of treatment results in short-term. One study found maxillary advancement stability in 80% of the cases of double- jaw surgery. Few relapses exceeded 4 mm. However, chin backward rotation of 2 mm occurred in 50% of the cases, being larger than 4 mm for 15% to 20% [3,4]. Overall, surgical orthodontic treatment plan improved the proportion and balance between facial components. The patient stated that outcomes of treatment overcame his expectations, in terms of dentofacial aesthetics and oral health-related quality of life [14]. The team noticed the patient compliance on multiple orthodontic and surgical stages was essential to treatment success.

Conclusion

Surgical orthodontic treatment with individualized sequence achieved successful results in a Class III young adult with transversal, sagittal, and vertical skeletal discrepancy.

References

1. Uribe LMM, Vela KC, Kummet C, Dawson DV, Southard T. Phenotypic diversity in white adults with moderate to severe class III malocclusion. *Am J Orthod Dentofacial Orthop.* 2013;144:32-42.
2. Bui C, King T, Proffit W, Frazier-Bowers S. Phenotypic characterization of Class III patients a necessary background for genetic analysis. *Angle Orthod.* 2006;76:564-9.
3. Proffit WR, White RP Jr. Combined surgical-orthodontic treatment: How did it evolve and what are the best practices now? *Am J Orthod Dentofacial Orthop.* 2015;147:S205-15.
4. Ngan P, Moon W. Evolution of Class III treatment in orthodontics. *Am J Orthod Dentofacial Orthop.* 2015;148:2-36.
5. Park JH, Papademetriou M, Kwon YD. Orthodontic considerations in orthognathic surgery: Who does what, when, where and how? *Sem Orthod.* 2016;22:2-11.
6. Atac ATA, Karasu HA, Aytac D. Surgically assisted rapid maxillary expansion compared with orthopedic rapid maxillary expansion. *Angle Orthod.* 2006;76:353-9.
7. Koudstaal MJ, Smeets JBJ, Kleinrensink GJ, Schulten AJM, Van der Wal KGH. Relapse and stability of surgically assisted rapid maxillary expansion: An anatomic biomechanical study. *J Oral Maxillofac Surg.* 2009;67:10-14.
8. Canellas JV, Barros LM, Barros H, Medeiros JD, Medeiros P, Ritto FG. Sleep-disordered breathing following mandibular setback: A systematic review of the literature. *Sleep Breath.* 2016;20:387-94.
9. Rinaldi MRL, Azeredo F, de Lima EM, Rizzato SMD, Sameshima G, de Menezes LM. Cone- beam computed tomography evaluation of bone plate and root length after maxillary expansion using tooth-borne and tooth-tissue-borne banded expanders. *Am J Orthod Dentofacial Orthop.* 2018;154:504-16.
10. Rédua R, Rezende RA, Ferreira CEA, Bittencourt MR. A complex orthognathic surgical approach correcting a Class III malocclusion involving traumatic dental injuries and a maxilla fracture. *Am J Orthod Dentofacial Orthop.* 2019;155:702-13.
11. Rizzato SMD. Class III malocclusion with severe anteroposterior discrepancy. *Dental Press J Orthod.* 2012;17(5):178-89.
12. Rizzato SMD, Menezes LM, Filho JJC, Allgayer S. Conventional surgical-orthodontic approach with double-jaw surgery for a patient with a skeletal Class III malocclusion: Stability of results 10 years posttreatment. *Am J Orthod Dentofacial Orthop.* 2018;154:128-39.
13. Acar YB, Erdem NF, Acar AH, Erverdi AN, Ugurlu K. Is counterclockwise rotation with double jaw orthognathic surgery stable in the long-term in hyperdivergent Class III patients? *J Oral Maxillofac Surg.* 2018;76:1983-90.
14. Denadai R, Chou PY, Su YY, Lin HH, Ho CT, Lo LJ. The impacts of orthognathic surgery on the facial appearance and age perception of patients presenting skeletal class III deformity. *Plast Reconstr Surg.* 2020;145(4):1035-46.