


# Oral manifestations of syphilis: an epidemiological study in southern Brazil

MA Thums,\* VS Koth,\*  MAZ de Figueiredo,\* K Cherubini,\* FG Salum\*

\*Oral Medicine Division, Pontifical Catholic University of Rio Grande do Sul-PUCRS, Porto Alegre, Rio Grande do Sul, Brazil.

## ABSTRACT

**Background:** Syphilis is an infectious, sexually transmitted disease with varied oral manifestations, that can mimic other lesions. This study aimed to conduct an epidemiological survey of cases of syphilis, diagnosed from oral manifestations, establishing the sociodemographic profile of patients and clinical characteristics of oral lesions.

**Methods:** The medical records of patients with oral lesions of syphilis acquired were reviewed, and 109 cases were selected.

**Results:** The mean age of the patients was 34.4 years and, of these, 51% were male. In 105 cases, the disease was diagnosed in the secondary stage; in three cases, in the primary stage; and, in one case, in the tertiary stage. The cases of primary syphilis presented as single and ulcerated nodules, and the case of tertiary syphilis, as a necrotic lesion in the palate. In 86% of cases of secondary syphilis, there were multicentric lesions, presenting as grayish-white plaques (85%), associated or not with erosive and/or ulcerated lesions (33%), mostly affecting the labial mucosa and tongue. In 91.7% of cases painful symptoms were reported.

**Conclusion:** Considering the increase in syphilis, it is extremely important that dentists recognize its oral manifestations, because early diagnosis and treatment can minimize the risks of complications and transmission.

**Keywords:** Lues, oral manifestations, syphilis.

(Accepted for publication 26 February 2021.)

## INTRODUCTION

Syphilis is a contagious infectious disease caused by *Treponema Pallidum*, a gram-negative bacterium, which can be transmitted through sexual intercourse, blood transfusion, direct contact with lesions and contaminated objects.<sup>1,2</sup> The disease may also be congenital due to the vertical transmission from the pregnant woman to the fetus by a transplacental route.<sup>3,4</sup> *Treponema Pallidum* has the human being as its only host and cannot survive outside its natural host.<sup>5</sup> One theory suggests that syphilis originated in America as an endemic infectious disease and was then introduced to Europe by Spanish sailors of Christopher Columbus.<sup>6,7</sup> However, a second theory maintains that treponematoses already existed in Europe and was caused by a single microorganism, whose virulence increased over time, allowing sexual transmission and the triggering of epidemics. With the emergence of penicillin and other antibiotics there was a reduction in the incidence of the disease; however, syphilis never been fully eradicated.<sup>8</sup>

In its natural history, the disease may present in primary, secondary, latent (asymptomatic phase) and tertiary<sup>2,8,9</sup> stages. As soon as there is penetration of the microorganism into the human organism, its dissemination to the bloodstream and ganglia occurs. The initial lesion, also called chancre, occurs 10–90 days after exposure to *Treponema Pallidum* and manifests at the inoculation site as a painless ulcer, with hardened edges.<sup>2</sup> The secondary stage is characterized by the presence of skin lesions, oral lesions with varied aspects and also by systemic signs and symptoms such as malaise, weight loss, headache, fever, muscle pain and arthralgia.<sup>10</sup> The spectrum of clinical manifestations associated with the secondary stage is very large, mimicking many other diseases.<sup>11,12</sup> In the latent phase, the patient is free of lesions and symptoms, but remains positive to the serological test.<sup>2</sup> Tertiary syphilis occurs in about one third of untreated patients and the most common oral lesion of this stage is syphilitic gum, an ulcerated, nodular and painless lesion, which can cause destruction and palatine perforation.<sup>1,13</sup>

The increase in cases of syphilis in recent times can be explained by the increase in intravenous drug use, decrease in the practice of safe sex and greater number of sexual partners.<sup>14</sup> According to the Brazilian Ministry of Health, an increase in registered syphilis cases has been observed in recent years. In 2017, 119 800 cases of acquired syphilis were notified, meaning a rate of 58.1 cases per 100 thousand inhabitants.<sup>15</sup> Syphilis can be identified through its frequent and distinct oral manifestations and, often, the dentist is the first professional that the patient seeks for the correct diagnosis. Knowledge regarding oral mucosal lesions caused by this infectious disease is essential. Thus, the present retrospective study aimed to conduct an epidemiological survey of cases of syphilis, diagnosed from oral manifestations, in a reference service in Oral Medicine of southern Brazil, establishing the socio-demographic profile of patients, as well as the clinical characteristics of stomatological lesions.

## MATERIALS AND METHODS

The present retrospective, cross-sectional and observational study was approved by the Research Ethics Committee of the Pontifical Catholic University of Rio Grande do Sul—PUCRS (protocol 62113516.9.0000.5336). The study was carried out at Stomatology Service of São Lucas Hospital, PUCRS. The medical records of all patients diagnosed with oral manifestations of acquired syphilis between 1977 and 2019 were retrieved. Cases lacking serological confirmation (Venereal Disease Research Laboratory—VDRL; Fluorescent Treponemal Antibody Absorption—FTA-ABS or Rapid Plasma Reagin—RPR) were excluded. Patients' medical records were reviewed by a single examiner. For each patient, we collected the information for age, sex, race, relevant medical history, smoking and drinking habits, duration of oral lesions and presence of symptomatology. The stage of the disease, cutaneous manifestations, clinical aspect and localization of oral lesions were recorded. To describe the clinical aspect of lesions in the secondary stage, they were classified as erosive and/or ulcerative lesions and mucous patches (plaques covered with a gray or white pseudomembrane), associated or not with reddish macules.

For cases of syphilis in the secondary stage, the previous history of genital lesions was analysed. The data were analysed using descriptive and quantitative statistics using the statistical software SPSS, version 18.0 for Windows. The chi-square test was used to evaluate the variables stage, age range, race, sex and habits and Student *t* test was used to evaluate age according to sex distribution. The level of significance was set at 5%.

## RESULTS

We analysed 182 medical records of patients with oral lesions whose clinical suspicion was syphilis. A total of 109 cases were included in the study in which the diagnosis of the disease was confirmed by serological tests. Of these, 51% were male and 49% female. The age of the patients ranged from 16 to 81 years, with a mean of 34.4 ( $\pm 12.05$ ) years. The patients were mostly diagnosed in the secondary stage of the disease (105 cases,  $P = 0.000$ , Chi square test); in three cases, the disease was in the primary stage; and, in one case, in the tertiary stage. The majority of patients were Caucasians ( $P = 0.000$ ) aged between 21 and 40 years old ( $P = 0.000$ ), and there was no significant difference regarding sex distribution ( $P > 0.05$ ). The sociodemographic characteristics of the cases studied are presented in Table 1. When the age of the patients was analysed according to sex distribution, it was seen that male patients infected with syphilis were older than female ( $P = 0.000$ ; Student *t* test), Table 2.

The three cases of primary syphilis presented as ulcerated nodules, accompanied by regional lymphadenopathy. Patients had painful symptoms and lesions had been evolving for less than two months. These lesions were located in labial vermilion, dorsum of the tongue and buccal mucosa (Fig. 1). These three patients showed treponemic and nontreponemic positive serological exam.

In 90 (86%) of the 105 cases of secondary syphilis, there were multicentric oral lesions and in 15 (14%) cases the lesions involved only one site of the oral mucosa. The affected sites and clinical characteristics

**Table 1. Sociodemographic characteristics of patients ( $n = 109$ ) with syphilis diagnosed from oral manifestations**

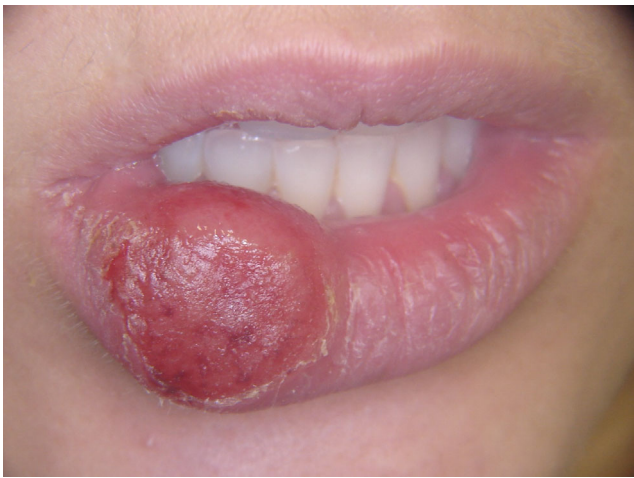Variables	$n = 109$	%
Stage of the disease		
Primary	3	2.75%
Secondary	105*	96.33%
Tertiary	1	0.91%
Age		
<20	12	11%
21-40	69*	63.3%
41-60	26	23.9%
61-80	2	1.8%
Race		
Caucasian	100*	91.7%
Black	—	—
Brown	3	2.8%
Not informed	6	5.5%
Sex		
Female (%)	53	49%
Male (%)	56	51%
Habits		
Tobacco use	54	49%
Alcohol consumption	12	11%

\* $P = 0.000$ ; Chi square test.

**Table 2. Average age of patients according to sex**

Sex	n	Age	P*
		Mean $\pm$ SD	
Total sample	109		
Male	56	38.2 $\pm$ 12.426	0.001
Female	53	30.4 $\pm$ 10.339	
Secondary stage	105		
Male	55	37.07 $\pm$ 13.336	0.006
Female	50	30.50 $\pm$ 10.136	

SD = standard deviation.

\*Student *t* test.**Fig. 1** Chancre located in lower labial vermilion, presenting as extensive nodular, ulcerated and firm consistency lesion

of the lesions are described in Table 3. The lesions in most cases presented as white or grayish-white plaques, of pearly aspect, associated with reddish macules (Fig. 2). In approximately 18% of cases, there was concomitant presence of mucosal plaques and erosive or ulcerative lesions (Fig. 3). Painful symptomatology was reported by 91.7% of patients, and duration of these lesions was on average three and a half months. In 43 (39.4%) cases, patients reported skin lesions concomitant with oral lesions, with the trunk being the most affected site, followed by the palms, abdomen, legs and plant of the feet. In 20% of cases of secondary syphilis, patients reported a history of genital lesion.

Tertiary syphilis was diagnosed in only one case. The patient did not present skin lesions or history of genital lesions. The stomatological lesion observed was the syphilitic gum, which was located on the palate, causing bone perforation (Fig. 4).

HIV serology was performed in 43 of the 109 cases analysed. In three of these cases, the result was positive.

## DISCUSSION

Oral manifestations of syphilis are frequent and often represent a diagnostic challenge, even in patients with

**Table 3. Clinical characteristics and location of oral lesions of syphilis in the secondary stage**

Clinical variables	n = 105	%
Clinical aspect		
Erosive and/or ulcerative lesions	33	31.4%
Mucous patches	85	80.9%
Location of lesions		
Labial mucosa	52	49.5%
Dorsum of the tongue	48	45.7%
Ventral tongue	40	38.1%
Palate	39	37.1%
Borders of tongue	32	30.4%
Buccal mucosa	32	30.4%
Tonsillary pillar	31	29.5%
Labial commissures	15	14.2%
Vestibule	9	8.5%
Gingiva/Alveolar mucosa	8	7.6%
Floor of mouth	7	6.6%

epidemiological risk factors.<sup>16</sup> The present retrospective study sought to describe the demographics, and clinical characteristics of acquired syphilis diagnosed through oral manifestations. One hundred and nine cases were included in the study, being one of the largest series of oral manifestations of syphilis ever presented. In 105 cases the disease was in the secondary stage, confirming data from the literature that patient's oral mucosa can be affected in all three stages, but it is most commonly affected in the secondary stage.<sup>8,13,17,18</sup> In the primary stage the lesion usually develops in the sex organs or in the perianal region. Despite the rise in incidence of syphilis, tertiary syphilis is exceedingly rare due to the wide availability of treatment, mainly in developed or developing countries.<sup>19</sup>

Oral manifestations of syphilis can take various, often nonspecific forms, simulating diverse diseases, such as lichen planus, traumatic ulcers, pemphigus vulgaris, leukoplakia, geographic tongue, hairy leukoplakia, among others.<sup>12,17,18</sup> Due to the wide variation of manifestations, syphilis is called 'a great imitator', and there is the necessity of including that disease in the differential diagnosis of unspecific oral ulcerations, erosions or whitish plaques. Accordingly, the clinical presentations found in this present study were diversified and classified into erosive /ulcerative lesions, aspect found in 33% of the cases; and greyish-white plaques, predominant aspect, that was observed in 85% of the patients. Different results were found by Matias et al.,<sup>17</sup> when analysing 85 medical records of patients with oral manifestations of syphilis. Only 20% of the lesions exhibited the appearance of mucous plaques, whereas the others presented as ulcerated lesions. Another important difference was that in our study 86% of the lesions were multicentric, whereas in the study by Matias et al.,<sup>17</sup>

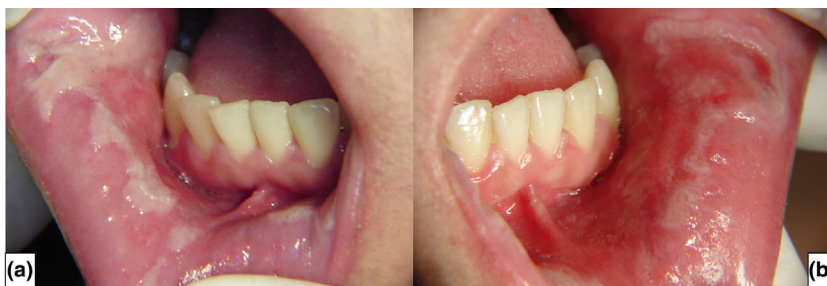

Fig. 2 Mucous patches, presenting as grayish-white plaques, of pearly aspect (a), associated with reddish macules (b)

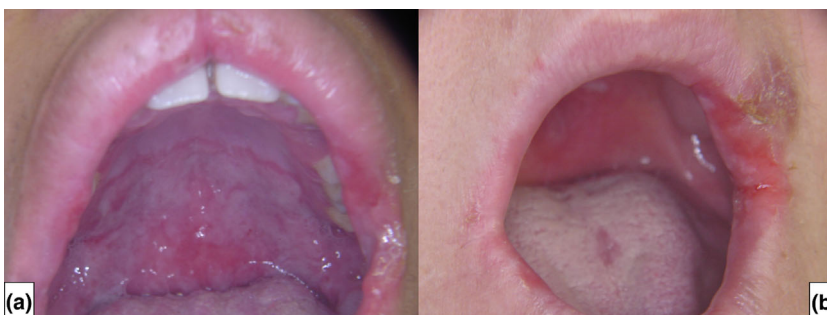

Fig. 3 Grayish-white mucous patches associated with reddish macules in soft palate (a) and erosive/ ulcerative lesions in labial commissure (b)

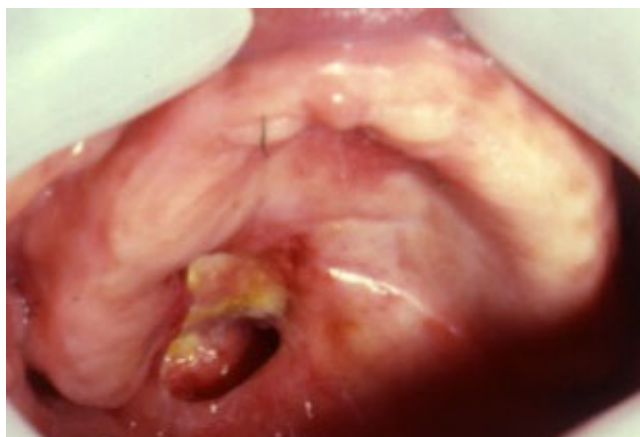

Fig. 4 Syphilitic gumma, presenting as a necrotic lesion, causing bone perforation in the palate

more than 90% of the lesions were unique, with an average duration of two weeks. A justification for the discrepant results in relation to the clinical aspect can be found in the time of evolution of the lesions, which in our study was three and a half months. The literature shows, however, that most oral lesions of secondary syphilis are multicentric, as observed in our study.<sup>10,13,20</sup> In both studies, the most affected sites were the lips and tongue, and in most cases the patients presented painful symptoms. In another study where 37 cases of secondary syphilis are described,<sup>18</sup> the clinical presentation was mostly a

combination of mucous patches and reddish ulcers and/or macules and half of patients showed multicentric involvement, showing that this disease has a wide variation of clinical features according to the studied population.

We observed that the disease affected individuals of all age groups, with 60% of the cases occurring between 20 and 40 years, which corroborates the literature<sup>7,18</sup> and can be justified by corresponding to the range of higher sexual activity. Male patients were older than women, which is in accordance with findings of Pires *et al.*<sup>21</sup> According to them, syphilis is becoming more frequent in older patients due to social and behavioural changes, like the use of drugs to treat erectile dysfunction. The distribution of cases was similar between females and males, differing from the study by Lampros *et al.*<sup>16</sup> These authors described a series of 38 cases of secondary syphilis with oral manifestations, of which 95% occurred in males. One third of these patients had HIV infection. In 30 of the 85 cases described by Matias *et al.*,<sup>17</sup> HIV tests were performed, and 28 obtained positive results. On the other hand, in the present study, only three patients out of 43 had HIV. Kelner *et al.*<sup>22</sup> stated that even though HIV patients may be more affected by syphilis, none of the patients described in their series of cases were infected, which also happened in the study of Pires *et al.*<sup>21</sup> We could speculate that the low frequency of patients with HIV in studies performed by stomatologists could be attributed to the fact that

these patients are under follow up with infectologist, who probably diagnose syphilis in early stages.

Another interesting finding in the present study was a higher frequency (91.7%) of Caucasians, which agrees with another study performed in the south of Brazil by Schuch et al.<sup>18</sup> However, this finding could be attributed to characteristics of the population at this geographical location since the colonization process was developed by German and Italian immigrants, resulting into a majority of Caucasians over blacks, browns or indigenous.<sup>23</sup> In addition, this study was conducted in a specialized centre of Stomatology and therefore can show disparities from epidemiological studies that screen the population, which show that vulnerable population groups are more prone to syphilis infection. Among them, black people and native indigenous show the higher indices of the infection in which the vulnerability is related to the knowledge, attitude, and practices studied in those groups.<sup>24,25</sup> The native indigenous in Brazil show a prevalence of syphilis that can be twice higher as the general population. This happens in a similar way to other natives such as indigenous of other Latin countries and the United States.<sup>24–26</sup> On the native communities of Aboriginal in Australia, in turn, syphilis infection reached such high indices in the past decade that it has reached values 100 times higher than the general Australian population.<sup>27</sup> However, after implementation of public health interventions among natives, there was a decreased in the transmission of syphilis among them,<sup>28</sup> shown by the low notification rate in comparison to the nation as a whole.<sup>28</sup> On the other hand, in Brazil, the prevalence of syphilis did not decrease among native indigenous even after implementation of syphilis control program in Amazon<sup>26,29</sup> which is even more serious because of the underreporting among natives.<sup>30</sup> Indigenous population show lower knowledge regarding sexually transmitted infections and preventive practices. In addition, higher risk behaviour can be observed among them, such as lower condom use.<sup>25,26</sup>

This was a single-centre study, and the research was performed with a population diagnosed through oral lesions. The population presented certain characteristics representative of the epidemiology of syphilis in Porto Alegre, Brazil, which may justify some differences found in relation to other studies. One limitation to be highlighted is that retrospective studies are dependent on how complete the information is. In addition to these issues, another deficiency of the study is that the cutaneous manifestations of secondary syphilis were based on the information reported by the patients, because the examination was performed by a stomatologist.

Considering the significant growth of syphilis cases in recent years,<sup>14,15</sup> this epidemiological survey was

important to trace the profile of patients affected by the disease and the clinical characteristics of oral lesions in the population studied. It is extremely important that dentists and other health professionals recognize the signs and symptoms of patients with mouth lesions of syphilis, which allows early diagnosis and treatment, minimizing the risks of transmission and complications resulting from this infectious disease.

## ACKNOWLEDGEMENT

We thank Fundação de Amparo à Pesquisa do Estado do Rio Grande do Sul (FAPERGS, Brazil) for the support received.

## ETHICS STATEMENT

This research was approved by Research Ethics Committee of the Pontifical Catholic University of Rio Grande do Sul—PUCRS (protocol 62113516.9.0000.5336). The study was performed according to the ethical standards of the Declaration of Helsinki.

## CONFLICT OF INTEREST

The authors declare that they have no conflicts of interest.

## REFERENCES

1. Leão JC, Gueiros LA, Porter SR. Oral manifestations of syphilis. *Clinics* 2006;61:161–166.
2. McNamara M, Yingling C. The Reemergence of syphilis: clinical pearls for consideration. *Nurs Clin North Am* 2020;55:361–377.
3. Peeling RW, Mabey D, Kamb ML, Chen XS, Radolf JD, Benzaiken AS. Primer: Syphilis. *Nat Rev Dis Prim* 2017;3:17073.
4. Nissanka-Jayasuriya EH, Odell EW, Phillips C. Dental stigmata of congenital syphilis: a historic review with present day relevance. *Head Neck Pathol* 2016;10:327–331.
5. Woods CR. Syphilis in children: congenital and acquired. *Semin Pediatr Infect Dis* 2005;16:245–257.
6. Rothschild B. History of syphilis. *Clin Infect Dis* 2005;40:1454–1463.
7. Ficarra G, Carlos R. Syphilis: the renaissance of an old disease with oral implications. *Head Neck Pathol* 2009;3:195–206.
8. De Andrade RS, De Freitas EM, Rocha BA, Gusmão EDS, Filho MRM, Júnior HM. Oral findings in secondary syphilis. *Med Oral Patol Oral y Cir Bucal* 2018;23:e138–e143.
9. Garnett GP, Aral SO, Hoyle DV, Cates W, Anderson RM. The natural history of syphilis. *Sex Transm Dis* 1997;24:185–200.
10. Angus J, Langan SM, Stanway A, Leach IH, Littlewood SM, English JS. The many faces of secondary syphilis: a re-emergence of an old disease. *Clin Exp Dermatol* 2006;31:741–745.
11. Ghanem KG, Ram S, Rice PA. The modern epidemic of syphilis. *N Engl J Med* 2020;382:845–854.
12. Klausner JD. The great imitator revealed: syphilis. *Top Antivir Med* 2019;27:71–74.
13. Leuci S, Martina S, Adamo D, et al. Oral syphilis: a retrospective analysis of 12 cases and a review of the literature. *Oral Dis* 2013;19:738–746.

14. Rowley J, Vander HS, Korenromp E, *et al.* Chlamydia, gonorrhoea, trichomoniasis and syphilis. *Bull World Health Organ* 2019;97:548–562.
15. Dos Santos MM, Lopes AKB, Roncalli AG, De Lima KC. Trends of syphilis in Brazil: a growth portrait of the treponemic epidemic. *PLoS One* 2020;15:1–11.
16. Lampros A, Seta V, Gerhardt P, Isnard C, Husson C, Dupin N. Oral forms of secondary syphilis: an illustration of the pitfalls set by the great imitator. *J Am Acad Dermatol* 2020;84:348–353.
17. Matias MDP, de Jesus AO, Resende RG, Caldeira PC, de Aguiar MCF. Diagnosing acquired syphilis through oral lesions: the 12 year experience of an Oral Medicine Center. *Braz J Otorhinolaryngol* 2020;86:358–363.
18. Schuch LF, da Silva KD, de Arruda JAA, *et al.* Forty cases of acquired oral syphilis and a review of the literature. *Int J Oral Maxillofac Surg* 2019;48:635–643.
19. Solis RN, Kuhn BT, Farwell DG. An unusual case of tertiary syphilis behaving like tongue squamous cell carcinoma. *J Investig Med High Impact Case Rep* 2018;6:232470961882035.
20. de Paulo LFB, Servato JPS, Oliveira MTF, Durighetto AF, Zanetta-Barbosa D. Oral manifestations of secondary syphilis. *Int J Infect Dis* 2015;35:40–42.
21. Pires FR, Da Silva PJS, Natal RF, *et al.* Clinicopathologic features, microvessel density, and immunohistochemical expression of ICAM-1 and VEGF in 15 cases of secondary syphilis with oral manifestations. *Oral Surg Oral Med Oral Pathol Oral Radiol* 2016;121:274–281.
22. Kelner N, Rabelo GD, Da Cruz Perez DE, *et al.* Analysis of nonspecific oral mucosal and dermal lesions suggestive of syphilis: a report of 6 cases. *Oral Surg Oral Med Oral Pathol Oral Radiol* 2014;117:1–7.
23. Petrucelli JL, Saboia AL. Características étnico-raciais da população. Classificações e identidades. Estudos e análises. Informação demográfica e socioeconômica. Instituto Brasileiro de Geografia e Estatística—IBGE: Rio de Janeiro 2013.
24. Lieberman JA, Cannon CA, Bourassa LA. Laboratory perspective on racial disparities in sexually transmitted infections. *J Appl Lab Med* 2021;6:264–273.
25. Russell NK, Nazar K, Del Pino S, Gonzalez MA, Díaz Bermúdez XP, Ravasi G. HIV, syphilis, and viral hepatitis among Latin American indigenous peoples and Afro-descendants: a systematic review. *Rev Panam Salud Publica/Pan Am J Public Health* 2019;43:1–13.
26. Benzaken AS, Sabidó M, Brito I, *et al.* HIV and syphilis in the context of community vulnerability among indigenous people in the Brazilian Amazon. *Int J Equity Health* 2017;16:1–9.
27. Read PJ, Donovan B. Clinical aspects of adult syphilis. *Epidemiology of syphilis in Australia. Intern Med J* 2012;42:614–620.
28. Kwan KSH, Giele CM, Greville HS, Reeve CA, Lyttle PH, Mak DB. Syphilis epidemiology and public health interventions in Western Australia from 1991 to 2009. *Sex Health* 2012;9:272–279.
29. BRASIL\_Ministerio da Saude\_ Secretaria de Vigilância em Saúde. Boletim Epidemiológico. 2020. URL: <http://www.aids.gov.br/pt-br/pub/2020/boletim-sifilis-2020>. Accessed 10 February 2021.
30. Graeff SV, Arantes R. Underreporting of gestational, congenital and acquired syphilis among indigenous peoples in Mato Grosso do Sul State, Brazil, 2011–2014. *Epidemiologia e Serviços de Saúde*. 2014;26:2011–2014.

\*Address for correspondence

Valesca Sander Koth

Serviço de Estomatologia—Hospital São Lucas

PUCRS

Av. Ipiranga, 6690 Sala 231

CEP: 90610-000, Porto Alegre, RS

Brazil.

Email: [valesca.koth@acad.pucrs.br](mailto:valesca.koth@acad.pucrs.br)