

Maxillary Labial Frenum in Preschool Children: Variations, Anomalies and Associated Factors

Paulo Floriani Kramer */ Livia Mund de Amorim**/ Nilton de Moura Alves ***/
Henrique Castilhos Ruschel****/ Juliane Bervian*****/ Carlos Alberto Feldens *****

Objective: To investigate the prevalence of morphological and attachment variations of the maxillary labial frenum (MLF) and associated factors in preschool children. **Study Design:** A cross-sectional study was conducted with 1,313 children aged between zero and five years of age attending public nurseries in the city of Canoas in southern Brazil. Data were collected through a questionnaire addressing demographic, socioeconomic, and behavioral characteristics and a clinical examination of the MLF. Assessments of MLF morphology and attachment were based on the classification systems proposed by Sewerin and Mirko et al., respectively. **Results:** The most prevalent patterns were simple MLF (63.8%) and gingival attachment (51.1%). Morphological abnormalities were found in 21.6% of the preschoolers and 25.4% exhibited abnormal frenal attachment. Abnormalities in MLF morphology were more prevalent among girls ($p = 0.003$) and a significant reduction was found with the increase in age ($p < 0.001$). Attachment abnormalities were significantly more prevalent among girls ($p < 0.001$), the white ethnic group ($p = 0.005$), and children who used a pacifier ($p = 0.007$) and also reduced significantly with the increase in age ($p < 0.001$). **Conclusion:** Demographic and behavioral characteristics were associated with MLF morphology and attachment. The reduction in the prevalence of the outcomes with the increase in age suggests that surgical interventions in the first years of life may constitute overtreatment.

Keywords: labial frenum, child, epidemiology.

*Paulo Floriani **Kramer**, DDS, PhD, Associate Professor, Department of Pediatric Dentistry, Universidade Luterana do Brasil, Canoas, Brazil; Associate Professor, Department of Pediatric Dentistry, Pontificia Universidade Católica do Rio Grande do Sul, Porto Alegre, Brazil.

Livia Mund de **Amorim, DDS, PhD Student, Graduate Program in Dentistry, Universidade Luterana do Brasil, Canoas, Brazil.

***Nilton de Moura **Alves**, DDS, PhD Student, Graduate Program in Dentistry, Universidade Luterana do Brasil, Canoas, Brazil.

****Henrique Castilhos **Ruschel**, DDS, PhD, Assistant Professor, Department of Pediatric Dentistry, Universidade Luterana do Brasil, Canoas, Brazil.

*****Juliane **Bervian**, DDS, PhD, Assistant Professor, School of Dentistry, Universidade de Passo Fundo, Passo Fundo, Brazil.

*****Carlos Alberto **Feldens**, DDS, PhD, Associate Professor, Department of Pediatric Dentistry, Universidade Luterana do Brasil, Canoas, Brazil.

Corresponding author:

Carlos Alberto Feldens
Universidade Luterana do Brasil
Rua João Telles 185/1301-Porto Alegre, Rio Grande do Sul, 90035-121, Brazil
Phone: +55 (51) 9 9995.9774
Fax : +55 51 33113502
cafeldens@gmail.com

The Journal of Clinical Pediatric Dentistry Volume 46, Number 1/2022

INTRODUCTION

The primary function of the maxillary labial frenum (MLF) is to stabilize the upper lip and keep it in harmony with the growing bones of the maxilla.¹ In newborns, the MLF assists the orbicular muscle in suckling.²⁻⁴ However, divergences of opinion are found regarding the identification, classification, and clinical significance of the MLF in childhood.

The undersurface of the upper lip is not part of the routine clinical examination in pediatric dentistry. Subsequently, clinicians are unclear about what constitutes a typical or atypical appearance of the MLF. Nor it is known whether the morphology and attachment of this frenum have any functional consequences.^{1,4,5} Variations in the appearance of the MLF may be either misinterpreted as lesions or associated with clinical problems, both of which suggest premature, although unnecessary, surgical interventions.

Potentially, characteristics of the MLF may exert an influence on sucking movements, including breastfeeding.^{4,6} It has been suggested that the labial frenum can interfere with an infant's ability to flange the upper lip around the nipple.^{2,6} Moreover, the MLF has been associated with midline diastema and interference with effective toothbrushing, preventing adequate plaque removal.^{1,5,7} Depending on the morphology and attachment of the MLF, there may be an area of the greater retention of milk or other liquids, which could contribute to the occurrence of early childhood caries on the maxillary incisors.²

While there is evidence of age-dependent differences in frenal morphology and attachment in the permanent dentition,^{5,8} there is little evidence to support such differences in the primary dentition. Only a few epidemiological studies have described morphological types and variations in the attachment of the MLF in preschool children and the majority of these studies have methodological flaws, such as a small sample size. Moreover, no studies have described variations in MLF attachment and morphology during a year by year period or have investigated associations with behavioral and socioeconomic characteristics.

The recognition of variations in the morphology and attachment of the MLF in the first years of life could assist pediatric dentists in the identification of patterns of normality and avoid the occurrence of unnecessary surgical procedures. Moreover, the identification of demographic, socioeconomic, and behavioral characteristics associated with abnormalities in the morphology and attachment of the MLF could suggest new hypotheses for risk factors to be tested in cohort studies. Therefore, the aim of the present study was to describe morphological and attachment variations and anomalies of the MLF and investigate associated factors in preschool children in southern Brazil.

MATERIALS AND METHOD

Study design and participants

A cross-sectional study was conducted involving preschool children aged between zero and five years of age enrolled at public nurseries in the city of Canoas, which is located in the southern region of Brazil. The city has a population of approximately 324,000 inhabitants.

This study is part of an oral health census and received approval from the Ethics Committee of *Universidade Luterana do Brasil* (ULBRA). The parents/guardians signed a statement of informed consent prior to the children's participation. Children aged between zero and five years of age enrolled at the 31 public preschools in Canoas and their parents were invited to participate (n = 1,732) in the study. Children with one or more permanent teeth erupted, a current/past history of orthodontic treatment, congenital anomalies, and a history of surgery in the maxillary anterior region were excluded from the study. In addition, children with dental problems were referred for treatment.

Data collection

The fieldwork team consisted of six pairs – each with an examiner (dentist, MSc student) and an assistant (undergraduate student). All team members had undergone training to ensure an acceptable level of uniformity in the research procedures. Prior to the study, 30 children not included in the main sample were examined for the standardization of the diagnostic criteria. All divergent diagnoses were discussed until reaching a consensus. A data collection guide was produced including the study protocol, photographs of the types of MLF (including all possibilities of morphological and attachment variations), as well as the criteria and methodological details of the data collection process.

Data were collected through structured interviews made with the parents/guardians at the nurseries and oral clinical examinations. The questionnaire addressed information on the child's sex (male/female), age (years), ethnic group (white/nonwhite), and

behavioral variables [breastfeeding (whether or not the child had been breastfed), pacifier use (whether or not the child used/had used a pacifier) and baby bottle (whether or not the child used/had used a baby bottle)]. Socioeconomic data were recorded as possible confounders: monthly family income [total earning of family measured in Brazilian currency using the Brazilian monthly minimum wage (BMMW = US\$ 200) as reference and categorized as < 1.5 times the BMMW; 1.5 to 2.0 times the BMMW; and > 2.0 times the BMMW] and mother's education (recorded in years of schooling and categorized as ≤ eight and > eight years).

The children were examined under natural light while lying on an adapted school desk of a classroom. The clinical examinations of the MLF were exclusively visual and performed using the fingers to elevate and distend the upper lip to enable the visual inspection of the frenum. Appropriate biosafety measures were observed during all procedures.

The morphological classification of the MLF was based on the typology described by Sewerin et al. (1971)⁹: *simple frenum*, soft tissue fold located on the median plane and connecting the labial mucosa to the connective tissue surrounding the alveolar bone; *simple frenum with appendix*, loose soft tissue extension inserted into the free border of the frenum; *simple frenum with nodule*, a large structure resembling a nodule, i.e., firm, whitish mass located on and incorporated into the free border of the frenum; *bifid frenum*, characterized by a vertical sulcus at the midline; *frenum with a niche*, invaginations of the mucous membrane of the frenum or surrounding tissues; *persistent tectolabial frenum*, frenum combined with diastemas between the maxillary central incisors and inserted into the area of the incisive papilla; and *double frenum*, variation characterized by duplication of the frenum. For the purposes of statistical analysis, frenum types were dichotomized as normal (simple, simple with appendix, and simple with nodule) and abnormal (bifid, with a niche, persistent tectolabial, double, and any combination of variations).

MLF attachment was classified according to Mirko et al. (1974)¹⁰: *mucosal*, frenum attached to the alveolar mucosa, including the mucogingival junction; *gingival*, inserted into the attached marginal gingiva; *papillary*, attached to interdental papillae; and *penetrating*, frenum crossing the gingival papillae and extending to the interdental gingiva. For the purposes of statistical analysis, frenum attachment was classified as either normal (mucosal and gingival) or abnormal (papillary and penetrating).

Data analysis

Statistical analysis was carried out using the Statistical Package for Social Sciences (SPSS, version 20.0). Associations between the independent variables and outcomes were first analyzed using the chi-squared test. Unadjusted and adjusted prevalence ratios of morphological and attachment abnormalities of the MLF were estimated in robust Poisson regression models. Prevalence ratios (PR) and 95% confidence intervals (95% CI) of all variables were first estimated separately. All variables in the crude model of each outcome were incorporated into the multivariate model. The level of significance was set to 5% (p < 0.05).

RESULTS

Among the 1,732 children enrolled at public preschools in the city of Canoas, dental exams were performed on 1,522 (response rate: 88%). The reasons for losses were repeated absences from preschool (n = 98), absence of a statement of informed consent signed by a parent/caregiver (n = 44), impossibility to perform the physical exam on the child (n = 38), and impossibility to contact the parent/caregiver for the interview (n = 30). Among the 1,522 children examined, 209 were excluded from the analysis due to the presence of permanent teeth (n = 197) and a history of orthodontic treatment (n = 12).

The final sample consisted of 1,313 children: 682 boys (52%) and 631 girls (48%). Age ranged from zero to five years (mean: 3.1; SD: 1.4). **Table 1** shows that the majority of child had white ethnicity (66.9%) and mother’s education ranged from zero to 16 years (mean: 9.5; SD: 2.7; median: 11). Income was low for most of the families, with almost two thirds living on a monthly income up to two times the Brazilian monthly minimum wage. Most children were/had been breastfed (78.1%), used/had used a pacifier (68.1%), and used/had used a baby bottle (91.8%).

The most frequent morphological patterns of the MLF were simple (63.8%), persistent tectolabial (14.2%), and simple with appendix (11.3%), whereas the most frequent attachment patterns were gingival (51.1%), mucosal (19.6%), and penetrating (15.4%). The morphology and attachment of the MLF were significantly associated (p < 0.001; data not shown in table). Among the 838 children with a simple morphology, attachment was gingival in 560 (68.8%). Among the 187 children with persistent tectolabial morphology, attachment was penetrating in 136 (72.7%).

The prevalence of morphological and attachment abnormalities of the MLF was 21.6% and 25.4%, respectively. Figures 1 and 2 respectively illustrate the variation in MLF attachment and morphological anomalies. An accentuated reduction in the prevalence of both outcomes was found in children up to four years of age. The penetrating type accounted for the majority of attachment abnormalities and the tectolabial type accounted for the majority of morphological abnormalities. Table 2 shows significant associations between demographic characteristics and both morphological and attachment aspects of the MLF. The prevalence of both morphological (p = 0.001) and attachment abnormalities (p < 0.001) was higher in girls than boys. Moreover, the prevalence of morphological and attachment alterations decreased with age (p < 0.001) and white children exhibited more attachment abnormalities than nonwhite preschool children (p = 0.004). No significant differences were found with regards to socioeconomic variables. The prevalence of morphological and attachment abnormalities of the MLF was significantly higher in children who were not breastfed (p = 0.010 and 0.006, respectively) and those who used a pacifier (p = 0.022 and p < 0.001, respectively).

Table 3 displays the results of the crude and adjusted regression analyses regarding abnormalities in the morphology of the MLF. After the adjustment for confounders, the prevalence of morphology abnormalities was 34% higher in the female sex (PR = 1.34; 95% CI: 1.10 to 1.64). The prevalence of this outcome diminished 64% in children between two to three years of age (PR = 0.36; 95% CI: 0.29 to 0.44) and 76% in those between four to five years of age (PR = 0.24; 95% CI: 0.19 to 0.31) compared to children less than two years

Table 1. Distribution of sample according to sociodemographic, behavioral, and clinical variables.

Variable	Children	
	N	%
Sex		
Male	682	52.0
Female	631	48.0
Age (years)		
0	37	2.8
1	167	12.8
2	234	17.8
3	317	24.1
4	342	26.0
5	216	16.5
Ethnicity		
White	879	66.9
Nonwhite	434	33.1
Mother’s education		
≤ 8 years	462	36.1
> 8 years	817	63.9
Family income		
< 1.5 x BMMW	431	35.2
1.5 – 2.0 x BMMW	363	29.7
> 2.0 x BMMW	430	35.1
Breastfeeding		
Yes	986	78.1
No	277	21.9
Pacifier Use		
Yes	892	68.1
No	417	31.9
Baby Bottle		
Yes	1195	91.8
No	107	8.2
MLF- Morphology		
Simple	838	63.8
Persistent tectolabial	187	14.2
Simple with appendix	149	11.3
Double	44	3.4
Simple with nodule	43	3.3
Two or more variations	29	2.2
With a niche	12	0.9
Bifid	11	0.8
MLF - Attachment		
Gingival	723	51.1
Mucosal	257	19.6
Penetrating	202	15.4
Papillary	131	10.0

BMMW – Brazilian monthly minimum wage

of age. The associations with breastfeeding and pacifier use lost their significance after the adjustment for confounding variables.

Table 4 displays the results of the crude and adjusted regression analyses regarding abnormalities in the attachment of the MLF. The female sex was 39% more likely to have attachment abnormalities than the male sex (PR = 1.39; 95% CI: 1.17 to 1.65). The prevalence of this outcome diminished 58% in children between two to three years of age (PR = 0.42; 95% CI: 0.36 to 0.50) and 81% in those between four to five years of age (PR = 0.19; 95% CI: 0.14 to 0.24) compared to children less than two years of age. Moreover, the prevalence of MLF attachment abnormalities was significantly higher in children with white ethnicity (PR = 1.33; 95% CI: 1.09 to 1.63) and those who used a pacifier (PR = 1.38; 95% CI: 1.09 to 1.73). The association with breastfeeding lost its significance after the adjustment for confounding variables.

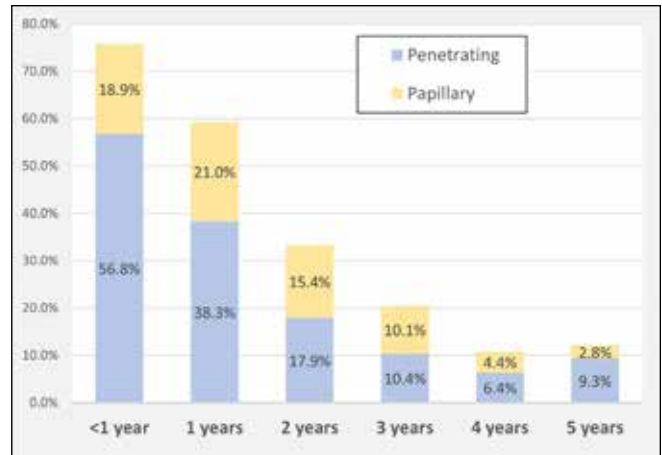


Figure 1. MLF attachment abnormalities according to age.

Table 2. Association between morphological and attachment aspects of maxillary labial frenum and demographic/behavioral variables.

Variable	Morphology			Attachment		
	Normal	Abnormal	p	Normal	Abnormal	p
TOTAL	1030 (78.4)	283 (21.6)		980 (74.6)	333 (25.4)	
Sex			0.001			<0.001
Male	559 (82.0)	123 (18.0)		541 (79.3)	141 (20.7)	
Female	471 (74.6)	160 (25.4)		439 (69.6)	192 (30.4)	
Age						
0	9 (24.3)	28 (75.7)	<0.001	9 (24.3)	28 (75.7)	<0.001
1	86 (51.5)	81 (48.5)		68 (40.7)	99 (59.3)	
2	179 (76.5)	55 (23.5)		156 (66.7)	78 (33.3)	
3	268 (84.5)	49 (15.5)		252 (79.5)	65 (20.5)	
4	303 (88.6)	39 (11.4)		305 (89.2)	37 (10.8)	
5	185 (85.6)	31 (14.4)		190 (88.0)	26 (12.0)	
Ethnicity			0.173			0.004
White	680 (77.4)	199 (22.6)		635 (72.2)	244 (27.8)	
Nonwhite	350 (80.6)	84 (19.4)		345 (79.5)	89 (20.5)	
Mother's education			0.629			0.814
≤ 8 years	365 (79.0)	97 (21.0)		346 (74.9)	116 (25.1)	
> 8 years	636 (77.8)	181 (22.2)		607 (74.3)	210 (25.7)	
Family income			0.031			0.083
< 1.5 x BMMW	348 (80.7)	83 (19.3)		332 (77.0)	99 (23.0)	
1.5 – 2.0 x BMMW	286 (78.8)	77 (21.2)		268 (73.8)	95 (26.2)	
> 2.0 x BMMW	321 (74.7)	109 (25.3)		309 (71.9)	121 (28.1)	
Breastfeeding			0.010			0.006
Yes	787 (79.8)	199 (20.2)		750 (76.1)	236 (23.9)	
No	201 (72.6)	76 (27.4)		188 (67.9)	89 (32.1)	
Pacifier Use			0.022			<0.001
Yes	684 (76.7)	208 (23.3)		638 (71.5)	254 (28.5)	
No	343 (82.3)	74 (17.7)		338 (81.1)	79 (18.9)	
Baby Bottle			0.804			0.228
Yes	937 (78.4)	258 (21.6)		886 (74.1)	309 (25.9)	
No	85 (79.4)	22 (20.6)		85 (79.4)	22 (20.6)	

BMMW – Brazilian monthly minimum wage

Table 3. Prevalence ratios (PR) and respective 95% confidence intervals (CI) in analysis of factors associated with morphology of maxillary labial frenum.

Variable	Unadjusted			Adjusted*		
	PR	95% CI	p	PR	95% CI	p
Sex			0.001			0.003
Male	1.00			1.00		
Female	1.40	(1.14-1.73)		1.34	(1.10-1.64)	
Age			<0.000			
0-1 years	1.00			1.00		<0.001
2-3 years	0.35	(0.28-0.43)		0.36	(0.29-0.44)	
4-5 years	0.23	(0.18-0.30)		0.24	(0.19-0.31)	
Ethnicity			0.177			0.227
White	1.17	(0.93-1.46)		1.14	(0.92-1.42)	
Nonwhite	1.00			1.00		
Mother's education						
≤ 8 years	0.95	(0.76-1.17)	0.630	1.13	(0.90-1.41)	0.286
> 8 years	1.00			1.00		
Family income						
< 1.5 x BMMW	0.76	(0.59-0.97)	0.033	0.76	(0.60-1.00)	0.053
1.5 – 2.0 x BMMW	0.83	(0.64-1.08)	0.173	0.81	(0.63-1.03)	0.087
> 2.0 x BMMW	1.00			1.0		
Breastfeeding			0.008			0.681
Yes	1.00			1.00		
No	1.35	(1.08-1.70)		1.05	(0.83-1.32)	
Pacifier Use			0.025			0.063
Yes	1.31	(1.03-1.66)		1.28	(0.99-1.66)	
No	1.00			1.00		
Baby Bottle			0.805			0.183
Yes	1.05	(0.71-1.54)		0.76	(0.50-1.14)	
No	1.00			1.00		

BMMW – Brazilian monthly minimum wage; *Adjusted for other variables in final model and family income.

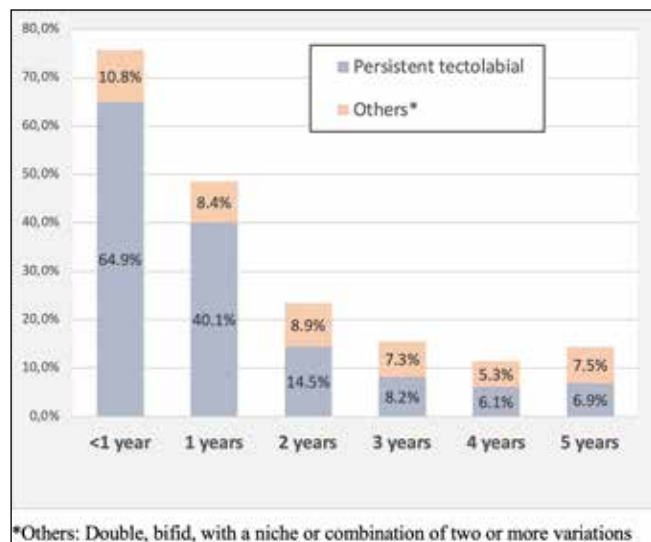


Figure 2. MLF morphological abnormalities according to age.

DISCUSSION

This study provides – for the first time – evidence of strong age-dependent differences in the morphology and attachment of the maxillary labial frenum in the primary dentition. Although three-quarters of the children exhibited anomalies in the morphology and attachment of the MLF in the first year of life, the prevalence diminished to less than 15% at five years of age. Persistent tectolabial frenum and penetrating frenum were the most frequent abnormalities. The frequency of MLF morphological and attachment anomalies was greater among girls, whereas no differences were found among socioeconomic strata. Moreover, attachment anomalies were more frequent among children in the white ethnic group and those who used a pacifier.

The most common MLF morphology was the simple frenum, which was found in more than three-quarters of the children in the present study. Similar frequencies have been reported in other communities.^{5,11-13} Frenum with a nodule and appendix are also considered normal, as these are considered developmental remnants with no pathological potential and do not require any investigation or treatment procedures.⁵ Persistent tectolabial frenum accounted for 14.2% of the morphological abnormalities in the present study. The prevalence of this abnormality ranges widely in previous studies from 1.7% to 24.6%.^{8,11} Other types of frenal abnormalities, such as frenum with a niche, double frenum, the bifid type, or the combination of two or more variations, are rarely found, affecting less than 1% of the population.¹²

Regarding MLF attachment, over half of the children exhibited gingival attachment and one-quarter exhibited papillary or penetrating variations. Previous studies report incidences of about 45%, 25%, 15%, and 10% for gingival, mucosal, papillary, and penetrating attachment, respectively.^{8,14,15} MLF attachment is highly associated with a number of syndromes, such as Ehlers–Danlos syndrome, infantile hypertrophic pyloric stenosis, holoprosencephaly, Ellis–van Creveld syndrome, and orofacial-digital syndrome. Each syndrome has relatively specific frenal abnormalities, such as multiple, hyperplastic, hypoplastic, or the absence of a frenum.^{1,5}

Morphological characteristics do not influence the attachment of the MLF in the permanent dentition, except for the persistent tectolabial presentation, for such attachment is always penetrating (i.e., inserting into the papillae).^{8,13} The results of the present study provide evidence – for the first time – of this hypothesis in the primary dentition, that the simple frenum is mainly inserted in the gingiva, while the persistent tectolabial type is penetrated the incisive papilla.

The evaluation of the distribution of different types of MLF morphology revealed that simple labial frenum increased significantly with age, whereas persistent tectolabial frenum decreased

Table 4. Prevalence ratios (PR) and respective 95% confidence intervals (CI) in analysis of factors associated with attachment of maxillary labial frenum.

Variable	Unadjusted			Adjusted *		
	PR	95% CI	p	PR	95% CI	p
Sex			<0.001			<0.001
Male	1.00			1.00		
Female	1.47	(1.22-1.77)		1.39	(1.17-1.65)	
Age			<0.001			<0.001
0-1 years	1.00			1.00		
2-3 years	0.41	(0.34-0.49)		0.42	(0.36-0.50)	
4-5 years	0.18	(0.14-0.23)		0.19	(0.14-0.24)	
Ethnicity			0.005			0.005
White	1.35	(1.09-1.67)		1.33	(1.09-1.63)	
Nonwhite	1.00			1.00		
Mother's education						
≤ 8 years	0.98	(0.80-1.19)	0.815	1.11	(0.92-1.35)	0.274
> 8 years	1.00			1.00		
Family income (minimum wages)						
< 1.5 x BMMW	0.82	(0.65-1.02)	0.083	0.87	(0.69-1.09)	0.217
1.5 – 2.0 x BMMW	0.93	(0.74-1.17)	0.536	0.93	(0.76-1.15)	0.523
> 2.0 x BMMW	1.00			1.00		
Breastfeeding			0.005			0.827
Yes	1.00			1.00		
No	1.34	(1.09-1.64)		1.02	(0.84-1.24)	
Pacifier Use			<0,001			0.007
Yes	1.50	(1.20-1.88)		1.38	(1.09-1.73)	
No	1.00			1.00		
Baby Bottle			0.243			0.357
Yes	1.25	(0.85-1.84)		0.83	(0.56-1.23)	
No	1.00			1.00		

BMMW – Brazilian monthly minimum wage; * Adjusted for other variables in final model.

significantly with age. Only one previous study has suggested this variation in the morphology of the MLF in preschool children.¹¹ Regarding the attachment of the MLF, the results show that the level of attachment also tends to move apically with age. Thus, younger children exhibited more papillary and penetrating types of attachment, whereas the gingival and mucosal types of attachment were more common in older children. A previous study had suggested that the prevalence of the papillary penetrating type is lower in children older than three years of age compared to those up to three years of age.¹⁶ However, this is the first study to describe this variation year by year in the primary dentition. The lower prevalence of abnormalities in the older children is compatible with findings reported for the permanent dentition.^{3,8} The frenum tends to migrate gingivally after the age of 5 years as the alveolar bone grows vertically with the eruption of the anterior maxillary teeth and the vertical growth of the face.

There is little evidence to support gender or ethnic differences in the MLF. The higher prevalence of morphological and attachment abnormalities in girls found in the present study differs from results reported in the literature for both the primary and permanent

dentitions.^{5,8,16,17,18} The greater likelihood of MLF attachment abnormalities in preschool children with white ethnicity has not previously been reported. Further studies are needed to establish possible associations between characteristics of the MLF in the primary and permanent dentition and both sex and ethnicity.

The finding that abnormal MLF attachment was 38% more likely in children who used/had used a pacifier cannot be compared to data from other studies because this is the first study to investigate this factor. Nonnutritive sucking habits are recognized as having an influence on oral myofunctional characteristics, such as the resting position of the lips and tongue, shape of the hard palate, and swallowing pattern.^{19,20} Moreover, the use of a pacifier is strongly associated with malocclusion in the primary dentition.^{21,22} It is therefore plausible that this habit – depending on its intensity, frequency, and duration – can alter the positioning of the MLF due to its influence on the development of the maxilla and upper lip.

Normal suckling begins with the flanging of the lips to create a seal around the areolar tissue of the breast.² Thus, anomalies in the attachment of the frenum could potentially limit the mobility and function of the upper lip, resulting in breastfeeding difficulties.^{2,6} However, no association was found between MLF morphological or attachment anomalies and breastfeeding. This

result lends support to data from a recent cohort study that found no associations between MLF morphology/attachment and comfort with breastfeeding, pain scores, or latching.²³ Moreover, a recent systematic review concluded that, to date, there is no evidence of the benefit of releasing the labial frenum to improve breastfeeding.²⁴

The clinical implications of the present study need to be discussed. The MLF has been mistakenly associated with several clinical problems, particularly the pathogenicity of midline diastema. However, diastema between the maxillary central incisors is a relatively common finding at the beginning of the primary and permanent dentitions. The findings of the present investigation showed that the tectolabial morphology and papillary/penetrating attachment of the MLF – considered the main candidates for surgical interventions – are highly prevalent in very young children.^{8,13} This situation increases the possibility of misdiagnosis in the first years of life and may result in unnecessary interventions on the frenum.

Moreover, tissue nodules and appendices are remnants that have no pathological potential and do not warrant biopsy. Hence, lack of knowledge regarding the various types of frenal morphology has resulted in unnecessary biopsies. Dentists should correlate the age of the child with the type of frenal attachment and morphological variations during clinical examinations to avoid misdiagnosis and unnecessary treatment. In rare cases, the MLF is exceptionally hypertrophic and can become traumatized and painful in the primary dentition phase.

This study has strengths that should be pointed out. First, the use of an internationally recognized diagnostic classification system strengthened by the ability to identify the outcomes. Secondly, although the cross-sectional design has inherent limitations that preclude the establishment of a temporal relationship between exposure factors and outcome, it is nonetheless effective at identifying associated factors that could be addressed in future longitudinal studies. Thirdly, the sample size was reasonably large, which enabled a reasonable degree of precision in the prevalence rates and effect measures.

CONCLUSIONS

The frequency of morphological and attachment anomalies of the maxillary labial frenum diminish considerably with the increase in age in early childhood. Moreover, there is no socioeconomic gradient in the distribution of such anomalies. The spontaneous reduction in morphological and attachment anomalies of the maxillary labial frenum and the lack of an association with breastfeeding suggest that dentists should be very cautious prior to opting for corrective surgical procedures, especially in the first years of life.

REFERENCES

1. Delli K, Livas C, Sculean A, Katsaros C, Bornstein MM. Facts and myths regarding the maxillary midline frenum and its treatment: a systematic review of the literature. *Quintessence Int.* 2013;44(2):177-187.
2. Kotlow LA. Diagnosing and understanding lip-tie (superior labial, the maxillary labial frenum) as it relates to breastfeeding. *J Hum Lact.* 2013;29(4):458-464.
3. Townsend JA, Brannon RB, Cheramie T, Hagan J. Prevalence and variations of the median maxillary labial frenum in children, adolescents, and adults in a diverse population. *Gen Dent.* 2013;61(2):57-60.
4. Santa Maria C, Aby J, Truong MT, Thakur Y, Rea S, Messner A. The superior labial frenum in newborns: What is normal? *Glob Pediatr Health.* 2017;4:1-6.
5. Biradar SM, Patil AY, Kotnoor SS, Bacha S, Bijjaragi SC, Kattimani PT. Assessment of diverse frenal morphology in primary, mixed, and permanent dentition: A prevalence study. *J Contemp Dent Pract.* 2020;21(5):562-567.
6. Pransky SM, Lago D, Hong P. Breastfeeding difficulties and oral cavity anomalies: The influence of posterior ankyloglossia and upper-lip ties. *Int J Pediatr Otorhinolaryngol.* 2015;79(10):1714-1717.
7. Gkantidis N, Kolokitha O-E, Topouzelis N. Management of maxillary midline diastema with emphasis on etiology. *J Clin Pediatr Dent.* 2008;32(4):265-272.
8. Sekar R, Mungara J, Joseph E. To determine the prevalence of maxillary labial and mandibular lingual frenum and its relationship between the upper midline space and to clinically assess the maxillary labial frenum morphology in 3 to 14 years children of Chennai city. *Glob J Res Anal.* 2019;8(2):136-140.
9. Sewerin IP. Prevalence of variations and anomalies of the upper labial frenum. *Acta Odontol Scand.* 1971;29(4):487-496.
10. Mirko P, Miroslav S, Lubor M. Significance of the labial frenum attachment in periodontal disease in man. Part I. Classification and epidemiology

of the labial frenum attachment. *J Periodontol.* 1974;45(12):891-894.

11. Díaz-Pízan ME, Lagravère MO, Villena R. Midline diastema and frenum morphology in the primary dentition. *J Dent Child.* 2006;73(1):11-14.
12. Nagaveni, N; Umashankara K. Morphology of maxillary labial frenum in primary, mixed, and permanent dentition of Indian children. *J Cranio Max Dis.* 2014;3(1):5-10.
13. PT J, Thakur H, Galhotra A, Galhotra V, Gupta N. Maxillary labial frenum morphology and midline diastema among 3 to 12-year-old schoolgoing children in Sri Ganganagar city: A cross-sectional study. *J Indian Soc Pedod Prev Dent.* 2018; 36(3): 234-239.
14. Christabel SL, Gurunathan D. Prevalence of type of frenal attachment and morphology of frenum in children, Chennai, Tamil Nadu. *World J Dent.* 2015;6(4): 203-207.
15. Seraj B, Shahrabi M, Masoumi S, Jabbarian R, Manesh AA, Fini MB. Studying maxillary labial frenulum types and their effect on median diastema in 3-6-year-old children in Tehran kindergartens. *World J Dent.* 2019;10(2):93-97.
16. Nadar S. Maxillary labium frenum in children of different age groups. *Int J Current Res.* 2017;9(5):50367-50369.
17. Upadhyay S, Ghimire N. Attachment of maxillary labial frenum in Nepalese children. *Orthod J Nepal.* 2012;2(1): 28-31.
18. Thosar N, Murarka P, Baliga S, Rathi N. Assessment of maxillary labial frenum morphology in primary, mixed and permanent dentitions in Wardha district. *Eur J Gen Dent.* 2017;6(1):14-17.
19. Melink S, Vagner MV, Hocevar-Boltezar I, Ovsenik M. Posterior cross-bite in the deciduous dentition period, its relation with sucking habits, irregular orofacial functions, and otolaryngological findings. *Am J Orthod Dentofacial Orthop.* 2010;138(1):32-40.
20. Nihi VSC, Maciel SM, Jarrus ME, Nihi FM, de Salles CLF, Pascotto RC, Fujimaki M. Pacifier-sucking habit duration and frequency on occlusal and myofunctional alterations in preschool children. *Braz Oral Res.* 2015;29(1):1-7.
21. Gois EG, Ribeiro Junior HC, Vale MP et al. Influence of nonnutritive sucking habits, breathing pattern and adenoid size on the development of malocclusion. *Angle Orthod.* 2008;78(4):647-654.
22. Moimaz SAS, Garbin AJI, Lima AMC, Lolli LF, Saliba O, Garbin CAS. Longitudinal study of habits leading to malocclusion development in childhood. *BMC Oral Health.* 2014;14(1):1-6.
23. Shah S, Allen P, Walker R, Rosen-Carole C, McKenna Benoit MK. Upper lip tie: anatomy, effect on breastfeeding, and correlation with ankyloglossia. *Laryngoscope.* 2020;00:1-6.
24. Nakhsh R, Wasserteil N, Mimouni FB, Kasirer YM, Hammerman C, Bin-Nun A. Upper Lip Tie and Breastfeeding: A Systematic Review. *Breastfeed Med.* 2019;14(2):83-87.